



<b>PATIENT</b>	<b>PRESENTING CLINICAL SIGNS</b>
Rusty Cordeiro	Limping occasionally, alternating in both front limbs. Physical exam shows no abnormalities. Neurological exam within normal limits.
<b>SPECIES</b>	<b>RADIOGRAPH OF SHOULDERS AND C-SPINE</b>
Canine	L fore leg: 2x lateral, R fore leg: lateral; both fore legs: 2x lateral; spine C2-T9 including fore legs and thorax: lateral and 3x VD; thorax: LLR
<b>BREED</b>	<b>RADIOGRAPHIC FINDINGS</b>
Labrador Mix	<u>C-spine</u>  The surrounding muscles and fat layers appear physiological.
<b>SEX</b>	Number and shape of the vertebrae are physiological. No signs of aggressive osteolysis have been identified.
Male Neutered	The disc spaces appear reduced between C3 and C7.
<b>AGE</b>	<u>Shoulders</u>
9 Years	The bones are well mineralized, have a normal trabecular structure and smooth, continuous surfaces. Cortical-medullary development and differentiation of the long bones are physiological.
<b>INTERPRETED BY</b>	The shoulder joints appear congruent with even subchondral bone surfaces.
Heike Rudolf, DVM, Dr. med. Vet., DipECVDI DVR	<b>RADIOGRAPHIC DIAGNOSIS</b>
<b>HOSPITAL NAME</b>	<ul style="list-style-type: none"> <li>I can see no abnormalities</li> </ul>
Truscott Animal Hospital	<b>INTERPRETATION OF THE FINDINGS &amp; FURTHER RECOMMENDATIONS</b>
<b>REFERRING VET</b>	Accurate positioning of the spine is difficult even under G.A. and cord compression can only be identified with myelography or in cross sectional imaging. Depending on the severity of the clinical signs, contrast-CT or MRI will be necessary to differentiate between disc extrusion, nerve root tumour and neuritis. Flexor myositis of the elbow can also be identified with both cross section al imaging methods. Bicipital tendon pathology can best be investigated ultrasonographically.
Dr. Medhat Meawad	<b>TECHNICAL COMMENTS</b>
<b>INVOICE</b>	Rotation lateral C-spine
50256	
<b>DATE</b>	
2-10-22	



**PATIENT**

Rusty Cordeiro

**SPECIES**

Canine

**BREED**

Labrador Mix

**SEX**

Male Neutered

**AGE**

9 Years

**INTERPRETED BY**

Heike Rudolf, DVM,  
Dr. med. Vet.,  
DipECVDDI DVR

**HOSPITAL NAME**

Truscott Animal  
Hospital

**REFERRING VET**

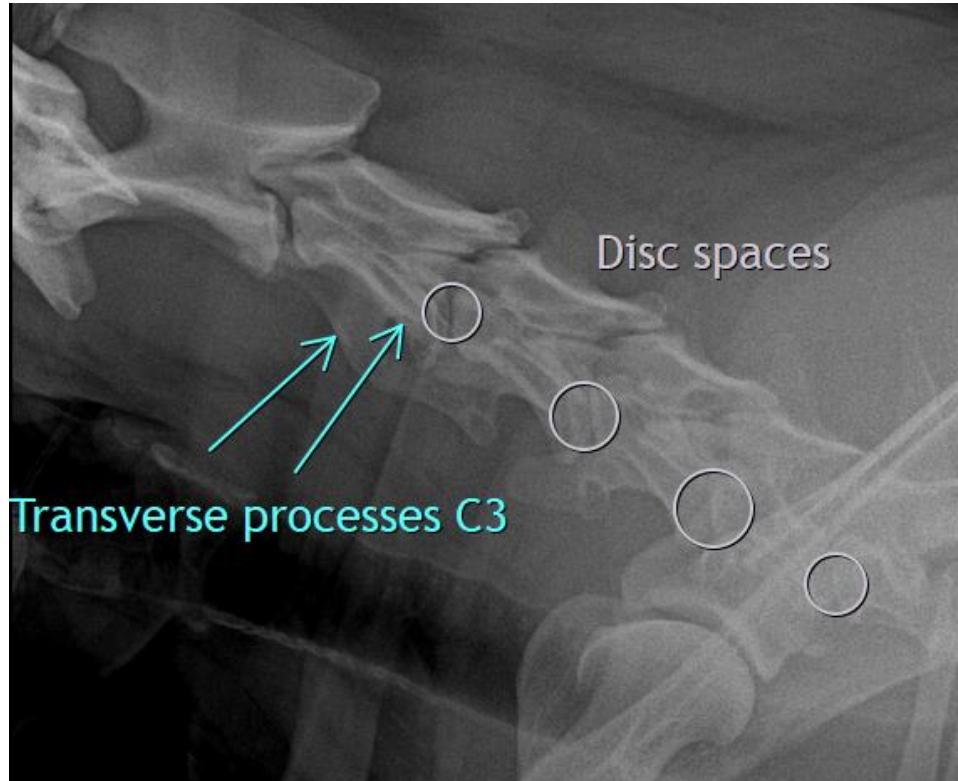
Dr. Medhat Meawad

**INVOICE**

50256

**DATE**

2-10-22



The information and recommendations provided are based on the images presented by the referring veterinarian/sonographer. No evaluation can be communicated regarding pathology that was not visible in the image/video clips provided.

Thank you for this referral. If the clinical or image interpretation does not parallel your findings or if I can be of any further assistance please contact me.

**Heike Rudolf, DVM, Dr. med. vet., DipECVDDI, DVR**  
Dr.H.Rudorf@gmail.com