



PATIENT PRESENTING CLINICAL SIGNS

Harry Sollen vomiting, not eating since Sunday, not using the litter box for 2 days
 Abnormal PE/Chem/CBC/UA Results: ear filled with black discharge, heart murmurs grade 3/6, moderate abdominal distension, bladder distended and not easy to be expressed, BW indicated low stress leukogram, mild anemia, low creatinine, high protein, high glucose, low K, Na.

SPECIES

Feline

RADIOGRAPH OF THORAX AND ABDOMEN

2 orthogonal views

BREED

Sphynx

RADIOGRAPHIC FINDINGS

The body condition score is 5/9 with a moderate amount of abdominal fat present.

SEX

The bony structures appear physiological.

Male

Thorax

The lungs are in contact with the thoracic boundaries and the tips are pointed. The lobar vessels are clearly visible to the tertiary branches. The bronchial walls are calcified, and the bronchi taper uniformly towards the periphery.

AGE

5 Years

The cranial mediastinum is of physiological size and opacity. The trachea diverges from the thoracic vertebrae and the carina is located at T6.

INTERPRETED BY

Heike Rudolf, DVM,
 Dr. med. Vet.,
 DipECVDI DVR

The cardiac silhouette occupies 80% of the chest height and 2.5 intercostal spaces. A suggestion of a Valentine shape is evident on the VD view.

Abdomen

HOSPITAL NAME

St. Catherine's Animal
 Hospital

The abdominal detail is good; diaphragm and abdominal wall are intact.

The liver is located within the costal arch and the caudo-ventral lobe is pointed.

The spleen appears physiological.

REFERRING VET

Dr. Masoud

The stomach is distended with air and the walls appear of homogeneous thickness; small intestinal loop distribution and size appear physiological. Colon and rectum contain a mixture of gas and fecal matter.

INVOICE

50253

Both renal shadows have a physiological size, shape and opacity. The bladder is located in the abdominal cavity and contains a large amount of homogeneous fluid opacity.

The sublumbar region appears physiological.

DATE

2-10-22

RADIOGRAPHIC DIAGNOSIS

- Stomach distended with air
- Valentoid shape of heart



PATIENT

Harry Sollen

SPECIES

Feline

BREED

Sphynx

SEX

Male

AGE

5 Years

INTERPRETED BY

Heike Rudolf, DVM,
Dr. med. Vet.,
DipECVDDI DVR

HOSPITAL NAME

St. Catherine's Animal
Hospital

REFERRING VET

Dr. Masoud

INVOICE

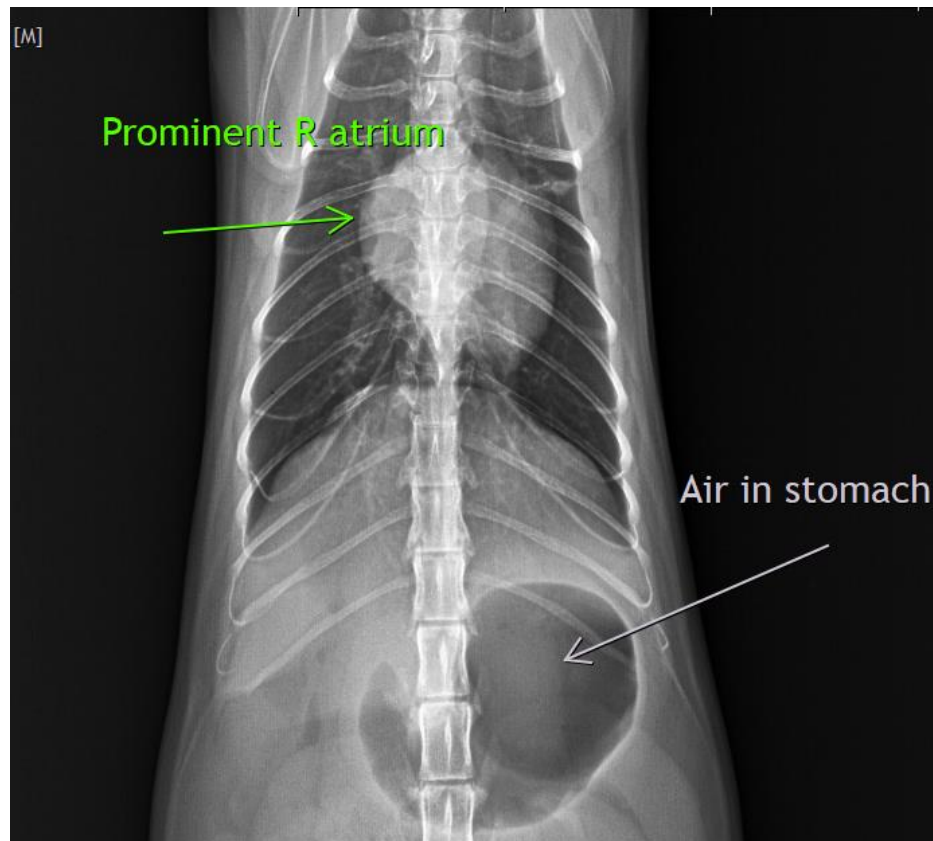
50253

DATE

2-10-22

INTERPRETATION OF THE FINDINGS & FURTHER RECOMMENDATIONS

I can see no changes that would explain the clinical sign of vomiting. The large amount of air in the stomach is most likely due to stress related aerophagia during radiography. Abdominal ultrasound is recommended to assess wall thickness and layering of the gastro-intestinal tract. Low sodium and potassium are likely due to the volume loss caused by the vomiting. Cardiac shape and murmur could be due to hypoperfusion (i.e. hemic murmur). Echocardiography is recommended if the murmur is still present after fluid therapy. Should conservative treatment not improve the clinical signs, checking B12 and folate as well as a fPL is recommended if it has not already been done.





PATIENT

Harry Sollen

The information and recommendations provided are based on the images presented by the referring veterinarian/sonographer. No evaluation can be communicated regarding pathology that was not visible in the image/video clips provided.

Thank you for this referral. If the clinical or image interpretation does not parallel your findings or if I can be of any further assistance please contact me.

SPECIES

Feline

Heike Rudolf, DVM, Dr. med. vet., DipECVDI, DVR
Dr.H.Rudorf@gmail.com

BREED

Sphynx

SEX

Male

AGE

5 Years

INTERPRETED BY

Heike Rudolf, DVM,
Dr. med. Vet.,
DipECVDI DVR

HOSPITAL NAME

St. Catherine's Animal
Hospital

REFERRING VET

Dr. Masoud

INVOICE

50253

DATE

2-10-22