


**PATIENT PRESENTING CLINICAL SIGNS**

Tanner Jacobs Ate a rubber backed rug yesterday.

**RADIOGRAPHIC STUDY OF THE ABDOMEN**
**SPECIES**

2 orthogonal views provided.

Canine

**RADIOGRAPHIC FINDINGS**
**BREED**

The body condition score is 5/9.

Poodle X

There is a step of 0.8cm between the ventral aspect of S1 and S2.

The abdominal detail is fair; diaphragm and abdominal wall are intact.

**SEX**

The liver extends just beyond the costal arch and the caudo-ventral lobe is pointed.

Male

The spleen appears physiological.

**AGE**

5/21/21

The stomach contains a moderate amount of air. Two crescent-shaped, gas filled intestinal loops are superimposed onto the left kidney in the left cranial abdomen. Their diameter is larger than that of the rest of the intestinal loops. Cranial to that two further gas containing loops are present. The colon appears to be located in the ventral abdomen, just dorsal to the tail of the spleen.

**INTERPRETED BY**

Both renal shadows are obscured by intestinal loops. The bladder neck is located just inside the pelvic canal.

Heike Rudolf, DVM,  
 Dr. med. Vet.,  
 DipECVDI DVR

The sublumbar region appears physiological.

**RADIOGRAPHIC DIAGNOSIS**
**HOSPITAL NAME**

- Localized ileus
- Sacral step ventral aspect (incidental finding)

Cottage Grove VC

**INTERPRETATION OF THE FINDINGS & FURTHER RECOMMENDATIONS**
**REFERRING VET**

Dr. Damewood

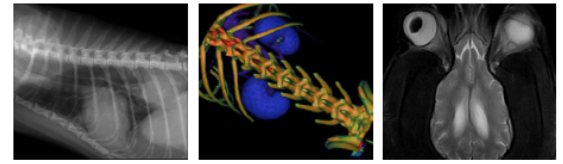
Due to the young age, the abdominal detail is poor and without fat surrounding the intestinal loops identification of their boundaries is difficult. However, this could be exacerbated by mesenteric inflammation (e.g. pancreatitis) or localized fluid. The localized small intestinal distension is suggestive of a partial obstruction. Evaluation by means of ultrasound is necessary. Alternatively, the radiographs should be repeated and if nothing has changed, surgery is recommended in light of the known intake of a foreign object.

**INVOICE**

33388

**DATE**

12/9/21



**PATIENT**

Tanner Jacobs

**SPECIES**

Canine

**BREED**

Poodle X

**SEX**

Male

**AGE**

5/21/21

**INTERPRETED BY**

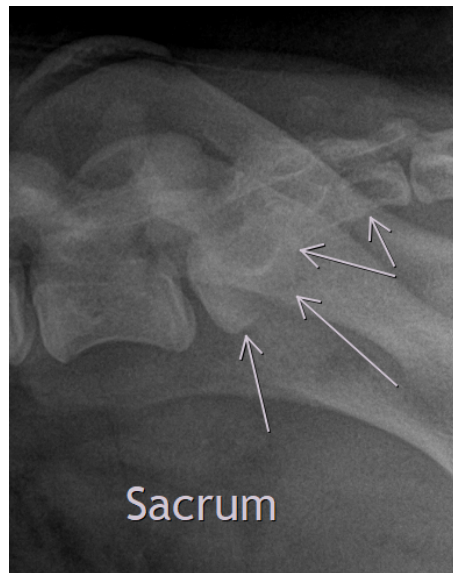
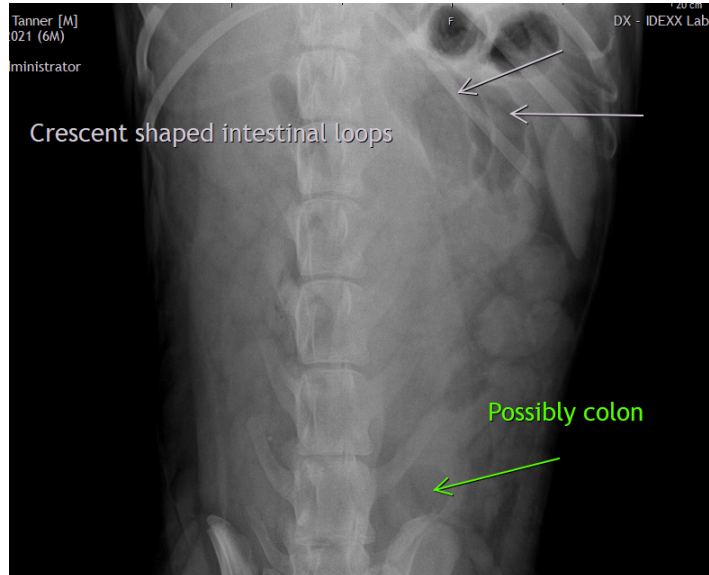
Heike Rudolf, DVM,  
Dr. med. Vet.,  
DipECVDI DVR

**HOSPITAL NAME**

Cottage Grove VC

**REFERRING VET**

Dr. Damewood



**INVOICE**

33388

**DATE**

12/9/21

The information and recommendations provided are based on the images presented by the referring veterinarian. No evaluation can be communicated regarding pathology that was not visible in the image/video clips provided.

Thank you for this referral. If the clinical or image interpretation does not parallel your findings or if I can be of any further assistance please contact me.

**Heike Rudolf, DVM, Dr. med. vet., DipECVDI, DVR**  
dr.h.rudorf@gmail.com