


PATIENT PRESENTING CLINICAL SIGNS

Suzie Mileto History of waxing/waning GI signs - mostly decreased appetite + picky with food for 2.5 weeks, had ultrasound on 11/30/21 with sonopath. Vomited once this AM. Did eat last night. Normal stool. Normal energy but does also wax and wane. Suspect foreign body in small intestines.

SPECIES Abnormal PE/Chem/CBC/UA Results: NSF

Canine **RADIOGRAPHIC STUDY OF THE ABDOMEN**

2x RLR, 1x LLR, 1x VD

BREED RADIOGRAPHIC FINDINGS

Pomsky X The body condition score is 7/9 with smooth alternating layers of fat and soft tissue opacity.

SEX The bony structures are within normal limits.

Spayed Female The abdominal detail is good; diaphragm and abdominal wall are intact.

The liver is located within the costal arch and the caudo-ventral lobe is pointed.

AGE The spleen appears physiological.

1 Year Variable amounts of gas are present in the small intestine, no distension is evident. A pod- shaped structure with two parallel, soft tissue dense, horizontal lines (0.2cm thick) and a slightly thinner cranial convex line is present in the descending colon and visible on all views.

INTERPRETED BY

Heike Rudolf, DVM, Dr. med. Vet., DipECVDI DVR The left renal shadow has a physiological size, shape and opacity; the surfaces are smooth. The bladder is located in the abdominal cavity and contains a small amount of homogeneous fluid opacity.

The sublumbar region appears physiological.

HOSPITAL NAME RADIOGRAPHIC DIAGNOSIS

Long Valley AH • Colonic foreign body

REFERRING VET INTERPRETATION OF THE FINDINGS & FURTHER RECOMMENDATIONS

Dr. Welch The movement of this foreign object would explain the ongoing clinical signs but since it has now passed the ileocecolic junction it should emerge "via naturalis". I would be interested to know what it actually was but assume the animal has passed it already.

INVOICE

33393

DATE

12/9/21



PATIENT

Suzie Mileto

SPECIES

Canine

BREED

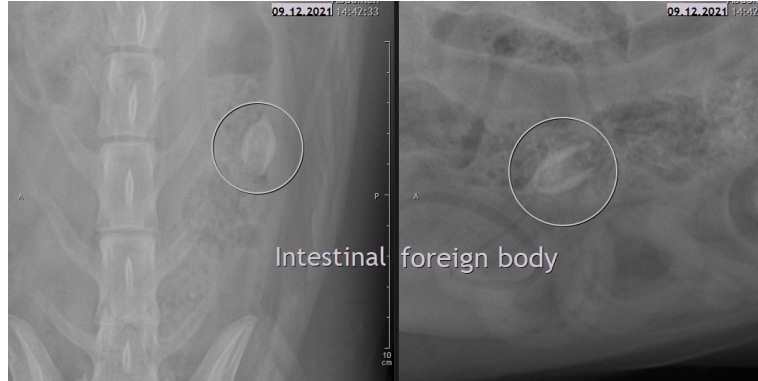
Pomsky X

SEX

Spayed Female

AGE

1 Year



The information and recommendations provided are based on the images presented by the referring veterinarian. No evaluation can be communicated regarding pathology that was not visible in the image/video clips provided.

Thank you for this referral. If the clinical or image interpretation does not parallel your findings or if I can be of any further assistance please contact me.

Heike Rudolf, DVM, Dr. med. vet., DipECVDI, DVR
dr.h.rudorf@gmail.com

INTERPRETED BY

Heike Rudolf, DVM,
Dr. med. Vet.,
DipECVDI DVR

HOSPITAL NAME

Long Valley AH

REFERRING VET

Dr. Welch

INVOICE

33393

DATE

12/9/21