


PATIENT PRESENTING CLINICAL SIGNS

Milo Gatto urinating and defecating around house.

RADIOGRAPHIC STUDY OF THE ABDOMEN
SPECIES

RLR, LLR, VD

Feline

RADIOGRAPHIC FINDINGS
BREED

The body condition score is 6/9 with smooth alternating layers of fat and soft tissue opacity.

DSH

The bony structures are within normal limits.

The abdominal detail is good; diaphragm and abdominal wall are intact.

SEX

The liver is located within the costal arch and the caudo-ventral lobe is pointed.

Neutered Male

The spleen appears physiological.

AGE

8 Months

The stomach contains a moderate amount of food; the small intestinal loops have a physiological distribution and are within normal limits for size; the gas containing small intestinal ones are slightly larger and appear stacked, though not closely, on the VD view. Colon and rectum contain a moderate amount of unformed fecal matter and islands of soft tissue opacity in the region of their gas. The height of the colon is approx. 3x the height of the vertebral body of L2.

INTERPRETED BY

Heike Rudolf, DVM,
 Dr. med. Vet.,
 DipECVDI DVR

Both renal shadows have a physiological size, shape and opacity; the surfaces are smooth. The bladder is located in the abdominal cavity and contains a moderate amount of homogeneous fluid opacity. The sublumbar region appears physiological.

RADIOGRAPHIC DIAGNOSIS
HOSPITAL NAME

Rockaway AH

- Variation in intestinal diameter
- Colon on upper limit of size range

INTERPRETATION OF THE FINDINGS & FURTHER RECOMMENDATIONS
REFERRING VET

Dr. Maniar

The changes in the gastrointestinal tract are non-specific and ultrasound is recommended to rule out hypermotility with slow moving ingesta and linear foreign body (though this is unlikely). Checking the size of the colon during subsequent, unrelated, physical examinations is recommended. A change of diet may improve the formation of intestinal gas. I cannot see an explanation for the behavior described.

INVOICE

33389

DATE

12/9/21



PATIENT

Milo Gatto

SPECIES

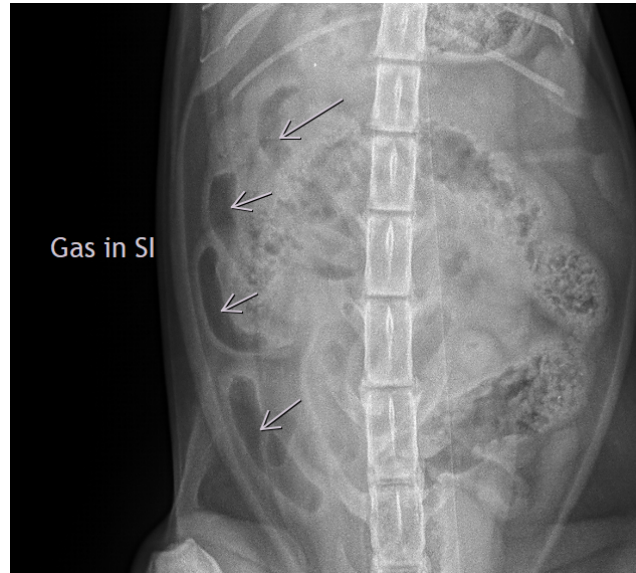
Feline

BREED

DSH

SEX

Neutered Male



AGE

8 Months

The information and recommendations provided are based on the images presented by the referring veterinarian. No evaluation can be communicated regarding pathology that was not visible in the image/video clips provided.

INTERPRETED BY

Heike Rudolf, DVM,
Dr. med. Vet.,
DipECVDI DVR

Thank you for this referral. If the clinical or image interpretation does not parallel your findings or if I can be of any further assistance please contact me.

Heike Rudolf, DVM, Dr. med. vet., DipECVDI, DVR
dr.h.rudorf@gmail.com

HOSPITAL NAME

Rockaway AH

REFERRING VET

Dr. Maniar

INVOICE

33389

DATE

12/9/21