



PATIENT PRESENTING CLINICAL SIGNS

Luna Safir History: acute onset coughing
Abnormal PE/Chem/CBC/UA Results:

SPECIES RADIOGRAPHIC STUDY OF THE THORAX

Canine The body condition score is 7/9 with smooth alternating layers of fat and soft tissue opacity. The ribs on the lateral views and the last 6 pairs of ribs on the VD view are straight.

BREED Lung expansion is good. A generalized interstitial pattern with loss of vascular outline and bronchial enhancement is present.

Chihuahua

Trachea and carina are parallel to the thoracic vertebrae. On the right lateral recumbent view the tracheal air space is reduced from dorsally between C3 and T1.

SEX

Spayed Female

The cardiac silhouette occupies 85% of the chest height and 3.5 intercostal spaces. The caudal border of the heart is straight, and the two main stem bronchi are displaced laterally.

AGE

10 Years

RADIOGRAPHIC DIAGNOSIS

- Interstitial pattern, generalized
- Cardiomegaly, left sided
- Tracheal collapse

INTERPRETED BY INTERPRETATION OF THE FINDINGS & FURTHER RECOMMENDATIONS

Heike Rudolf, DVM,
Dr. med. Vet.,
DipECVDI DVR

The generalized interstitial lung pattern is a non-specific finding but with good expansion of the lung field, possible differential diagnoses include:

HOSPITAL NAME

Rockaway AH

- Edema
- Hemorrhage
- Infection (bacterial, fungal e.g. candida, viral, Rickettsia, Spirochetes, parasitic)
- Inflammation (allergic e.g. eosinophilic bronchopneumonia and PIE, smoke inhalation)
- (Fibrosis and Tumor are less likely)

REFERRING VET

Dr. Maniar

Tracheal collapse alone can be due to a weakened dorsal tracheal ligament. Tracheal in combination with bronchial collapse is usually caused by chondromalacia and is thus due to an altered cartilage development which may go unnoticed until disease (e.g. pneumonia, bronchitis, left cardiac enlargement) or physical circumstances (such as stress, running, excitement) reduces the ease of airflow. Echocardiography to assess mitral valve and left atrial size and bronchoscopy to obtain a BAL is recommended. Should an underlying disease be present treatment may improve the clinical signs.

INVOICE

12781

DATE

12/9/21



PATIENT

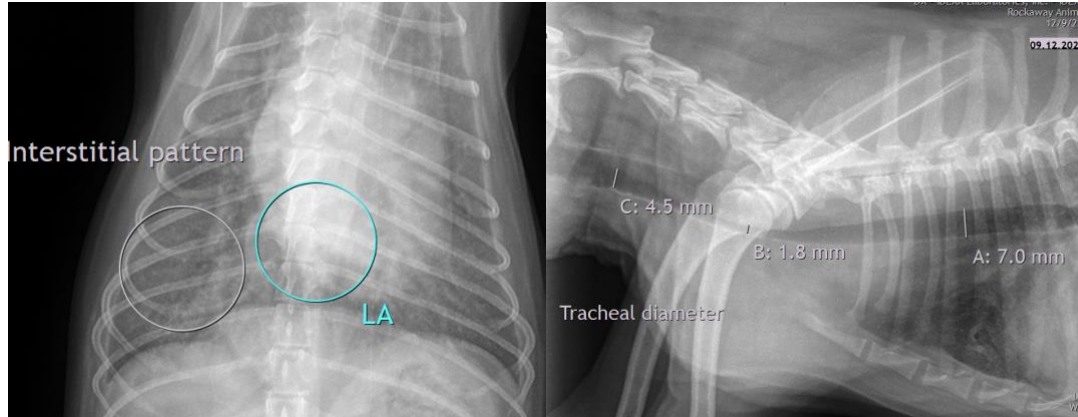
Luna Safir

SPECIES

Canine

BREED

Chihuahua



SEX

Spayed Female

AGE

10 Years

The information and recommendations provided are based on the images presented by the referring veterinarian. No evaluation can be communicated regarding pathology that was not visible in the image/video clips provided.

Thank you for this referral. If the clinical or image interpretation does not parallel your findings or if I can be of any further assistance please contact me.

Heike Rudolf, DVM, Dr. med. vet., DipECVDI, DVR
dr.h.rudorf@gmail.com

INTERPRETED BY

Heike Rudolf, DVM,
Dr. med. Vet.,
DipECVDI DVR

HOSPITAL NAME

Rockaway AH

REFERRING VET

Dr. Maniar

INVOICE

12781

DATE

12/9/21