

**PATIENT**

Dean Martin

**PRESENTING CLINICAL SIGNS**

Intermittent episodes of coughing and gagging. Routine geriatric diagnostics.

**SPECIES**

Canine

**RADIOGRAPHIC STUDY OF THE THORAX**Thorax:RLR, LLR, DV  
1x lateral abdomen

Thoracic read requested.

**BREED**

Great Pyreneese

**RADIOGRAPHIC FINDINGS**

The body condition score is 6/9 with smooth alternating layers of fat and soft tissue opacity.

**SEX**

MN

Spondylosis is present ventral to T4/5.

The lungs are in contact with the thoracic boundaries and the tips are pointed. The lobar vessels are clearly visible to the tertiary branches. The bronchial tree is thin walled and tapers uniformly towards the periphery.

**AGE**

10 Years, 7 Months

The cranial mediastinum is of physiological size and opacity. The trachea diverges from the thoracic vertebrae and the carina is located at T5.

**INTERPRETED BY**Heike Rudolf, DVM,  
Dr. med. Vet.,  
DipECVDDI DVR

The cardiac silhouette occupies 75% of the chest height and 2.5 intercostal spaces. No chamber or outflow tract enlargement is evident. A slightly undulating line of mineral opacity is evident on the right lateral recumbent view between ribs 4 and 5.

**RADIOGRAPHIC DIAGNOSIS**

- Possible coronoid artery calcification
- Spondylosis

**HOSPITAL NAME**Tahoe Intergrative  
Veterinary Care**INTERPRETATION OF THE FINDINGS & FURTHER RECOMMENDATIONS**

The apparent linear mineralization could represent a well outlined pulmonary vessel or calcified coronoid artery. Both would not explain the clinical signs.

**REFERRING VET**

Dr. Amanda Stuart

Bronchitis can be present without radiographic evidence and thus bronchoscopy with broncho-alveolar lavage is necessary to rule out bronchial infection and inflammation as well as tracheitis. At the same time the larynx can be checked for early laryngeal paralysis and the tonsils for enlargement.

**INVOICE**

48742

**DATE**

12-3-21



**PATIENT**

Dean Martin

**SPECIES**

Canine

**BREED**

Great Pyreneese

**SEX**

MN

**AGE**

10 Years, 7 Months

**INTERPRETED BY**

Heike Rudorf, DVM,  
Dr. med. Vet.,  
DipECVDDI DVR

**HOSPITAL NAME**

Tahoe Intergrative  
Veterinary Care

**REFERRING VET**

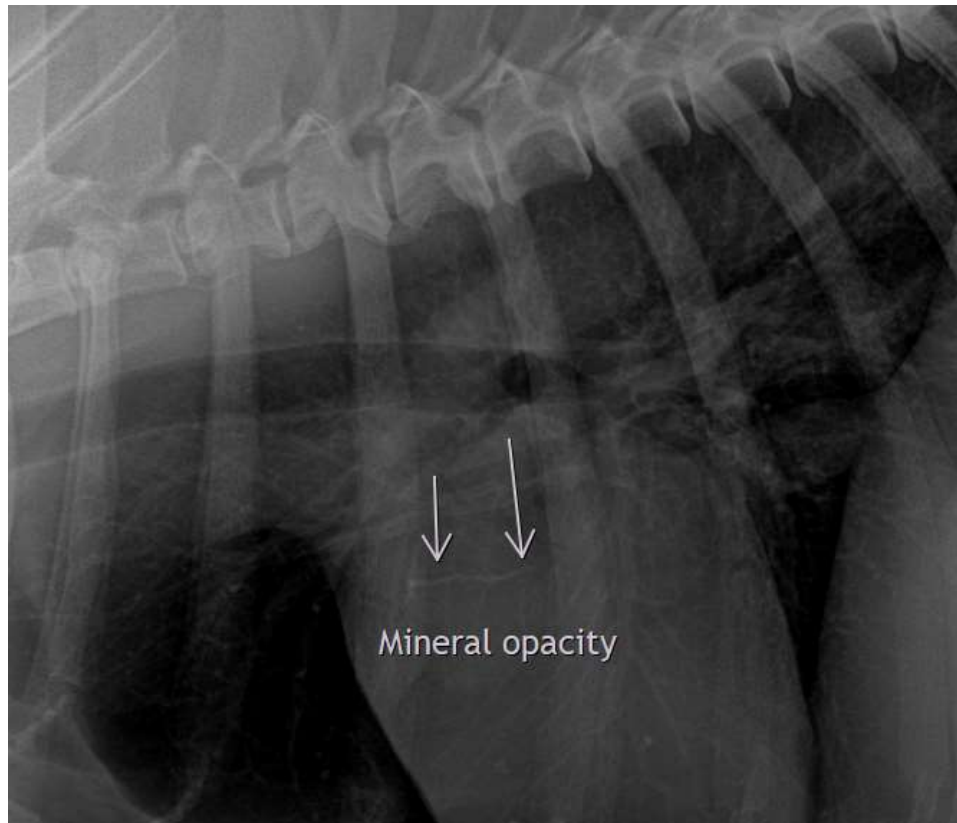
Dr. Amanda Stuart

**INVOICE**

48742

**DATE**

12-3-21



The information and recommendations provided are based on the images presented by the referring veterinarian. No evaluation can be communicated regarding pathology that was not visible in the image/video clips provided.

Thank you for this referral. If the clinical or image interpretation does not parallel your findings or if I can be of any further assistance please contact me.

**Heike Rudorf**, DVM, Dr. med. vet., DipECVDDI, DVR  
Dr.H.Rudorf@gmail.com