



PATIENT	PRESENTING CLINICAL SIGNS
Simba Engelman	Reason for Visit: vomiting, hard time chewing History: P presents for one episode of vomiting last night and not wanting to eat this morning. O states P has been eating his wet food normal but having difficulty chewing his kibble. P also gets hairball often and O gives P cat lax and lactulose when needed. Owner states cat has always vomited hairballs once weekly and this has recently increased in frequency. Defecates every other day.
SPECIES	Abnormal PE/Chem/CBC/UA Results: Oral cavity: Mild calculus. Ate Churu treat and part of pill pocket readily in exam room--no dysphagia or difficulty chewing observed. Abd/GI: Soft, non-painful. no fluid wave, no palpable masses or organomegaly, no fecal balls palpable on abdominal palpation BCS = 4/9. Ambulatory x 4, normal gait, mild to moderate muscle wasting Neurological: Alert and appropriate. No deficits noted
Feline	
BREED	
DSH	RADIOGRAPH OF THE ABDOMEN
SEX	2 orthogonal views
NM	RADIOGRAPHIC FINDINGS
AGE	The body condition score is 6/9 with a physiological amount of abdominal fat.
13 Years, 5 Months	Spondylosis is present L5/6.
INTERPRETED BY	The abdominal detail is good; diaphragm and abdominal wall are intact.
Heike Rudolf, DVM, Dr. med. Vet., DipECVDI DVR	The liver is located within the costal arch and the caudo-ventral lobe is pointed.
HOSPITAL NAME	The head of the spleen appears physiological.
DPC Veterinary Hospital	The stomach contains a moderate amount of food; the small intestinal loops have a physiological distribution and size. The colon contains a moderate amount of fecal matter. The visible part of the rectum contains solid feces.
REFERRING VET	Both renal shadows have a physiological size, shape and opacity. The bladder is located in the abdominal cavity and contains a moderate amount of homogeneous fluid opacity.
Ward	The sublumbar region appears physiological.
INVOICE	RADIOGRAPHIC DIAGNOSIS
49218	<ul style="list-style-type: none"> • Spondylosis • Solid feces in rectum
DATE	INTERPRETATION OF THE FINDINGS & FURTHER RECOMMENDATIONS
12-23-21	Solid feces in the rectum may cause pain during defecation and may need to be removed manually. In case vomiting persists or becomes more frequent, the animal should be starved for 24 hours and re-radiographed in case the stomach does not empty completely.
	Full hematology and biochemistry should be considered to detect early signs of organopathies (e.g. pancreatitis, renal failure).



PATIENT

Simba Engelman

TECHNICAL COMMENTS

Human fingers in primary beam on lateral view

SPECIES

Feline

BREED

DSH

SEX

NM

AGE

13 Years, 5 Months

INTERPRETED BY

Heike Rudolf, DVM,
Dr. med. Vet.,
DipECVDI DVR

HOSPITAL NAME

DPC Veterinary
Hospital

REFERRING VET

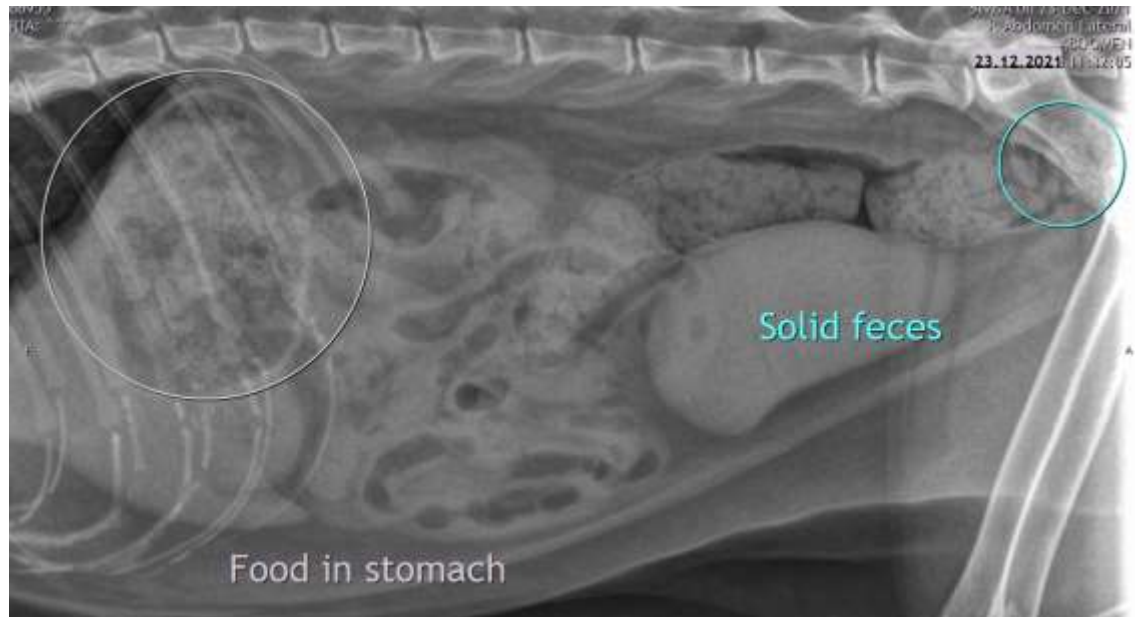
Ward

INVOICE

49218

DATE

12-23-21



The information and recommendations provided are based on the images presented by the referring veterinarian. No evaluation can be communicated regarding pathology that was not visible in the image/video clips provided.

Thank you for this referral. If the clinical or image interpretation does not parallel your findings or if I can be of any further assistance please contact me.

Heike Rudolf, DVM, Dr. med. vet., DipECVDI, DVR
Dr.H.Rudorf@gmail.com