



PATIENT PRESENTING CLINICAL SIGNS

Abby Davenport not sedated- laryngeal thickening. Neck Larynx possible mass - Thickening of the laryngeal area noted, possible mass like effect, stertor worsens with palpation of this area. Respiratory General findings Stertor All lung fields Referred upper airway sounds Respiratory effort Eupnea

SPECIES ULTRASONOGRAPHIC EXAMINATION OF THE NECK

Canine

1)

BREED

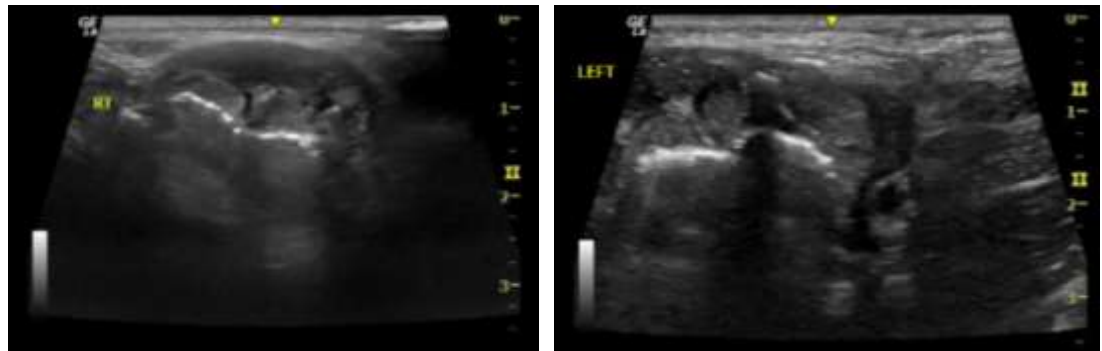
Beagle

SEX

FS

AGE

11 Years



Assuming these to be longitudinal images paralleling the trachea. They look similar to me.

WEIGHT

26.8 lbs

2)

INTERPRETED BY

Heike Rudolf, DVM, Dr.
med. Vet., DipECVDI DVR

IMAGING PERFORMED BY

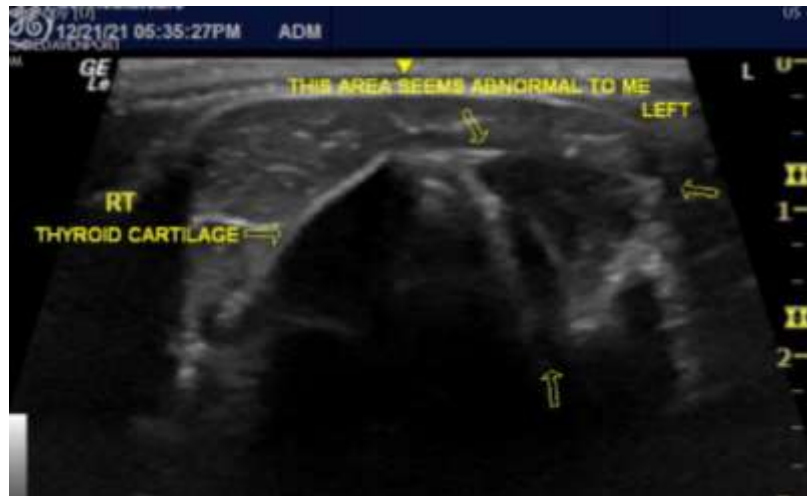
Loetitia Saint-Jacques, RVT

HOSPITAL NAME

VCA Lakeside Animal
Hospital

REFERRING VET

Dr. Park



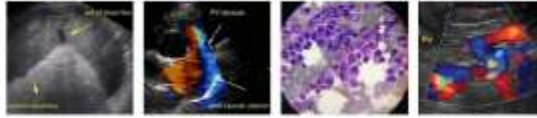
Assuming this to be a straight transverse view, the region surrounded by arrows would be abnormal. However, on one video clip this echogenicity seems to be present on both sides of the trachea just caudal to the larynx:

INVOICE

49225

DATE

12-23-21



PATIENT

Abby Davenport

SPECIES

Canine

BREED

Beagle

SEX

FS

AGE

11 Years

WEIGHT

26.8 lbs

INTERPRETED BY

Heike Rudolf, DVM, Dr.
med. Vet., DipECVDI DVR

IMAGING PERFORMED BY

Loetitia Saint-Jacques, RVT

HOSPITAL NAME

VCA Lakeside Animal
Hospital

REFERRING VET

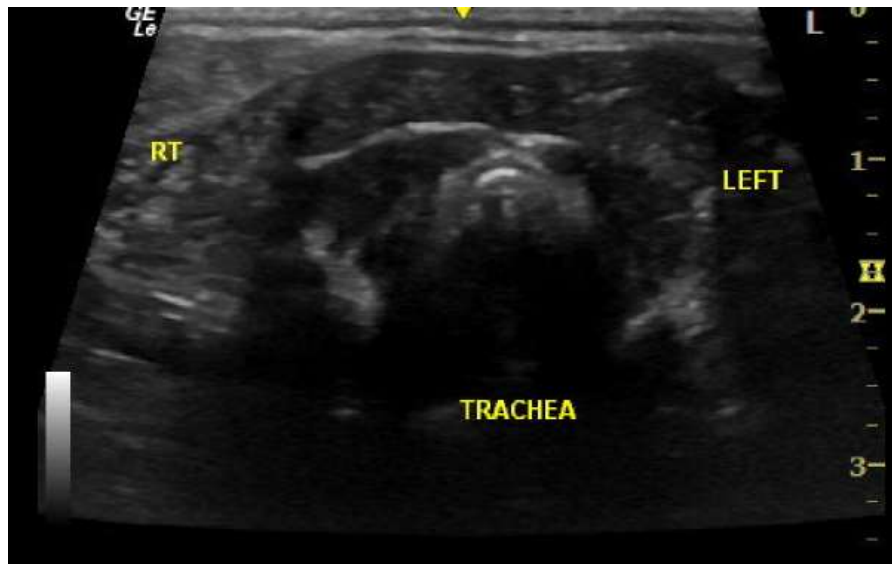
Dr. Park

INVOICE

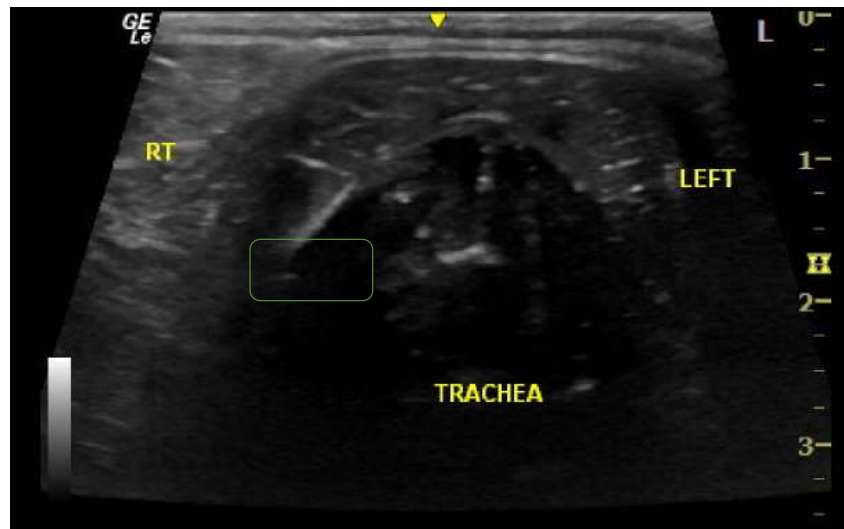
49225

DATE

12-23-21



followed by



normal larynx, laryngeal air in orange square.



PATIENT

Abby Davenport 3)

SPECIES

Canine

BREED

Beagle

SEX

FS

AGE

11 Years

WEIGHT

26.8 lbs

INTERPRETED BY

Heike Rudolf, DVM, Dr.
med. Vet., DipECVDDI DVR

IMAGING PERFORMED BY

Loetitia Saint-Jacques, RVT

HOSPITAL NAME

VCA Lakeside Animal
Hospital

REFERRING VET

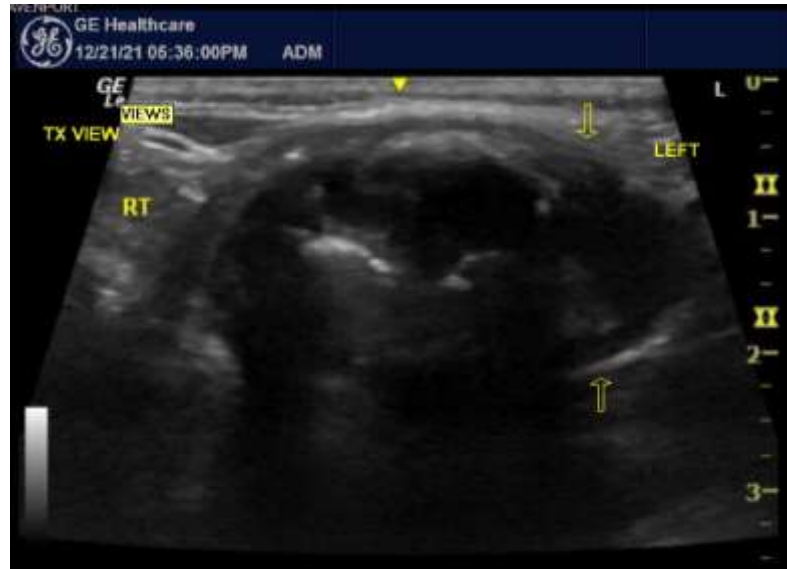Dr. Park

INVOICE

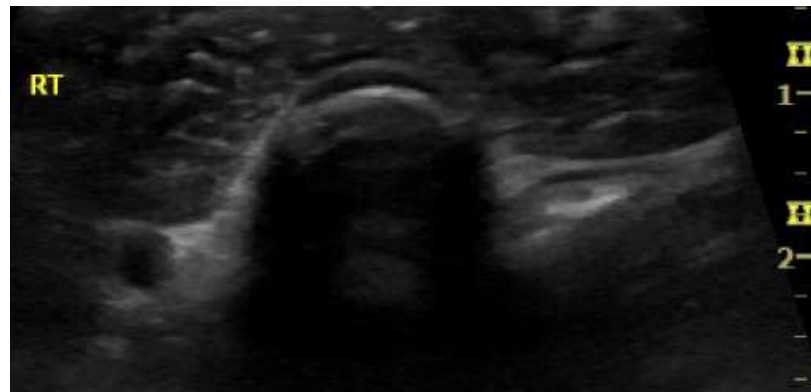49225

DATE

12-23-21



Assuming this to be a transverse view: if this is the trachea immediately caudal to the larynx, the hyperechoic air shadow appears to be divided into a right and a left component. The entire structure is large, thick and generally hypoechoic.



physiological, transverse trachea.



PATIENT

Abby Davenport 4)

SPECIES

Canine

BREED

Beagle

SEX

FS

AGE

11 Years

WEIGHT

26.8 lbs

INTERPRETED BY

Heike Rudolf, DVM, Dr.
med. Vet., DipECVDI DVR

IMAGING PERFORMED BY

Loetitia Saint-Jacques, RVT

HOSPITAL NAME

VCA Lakeside Animal
Hospital

REFERRING VET

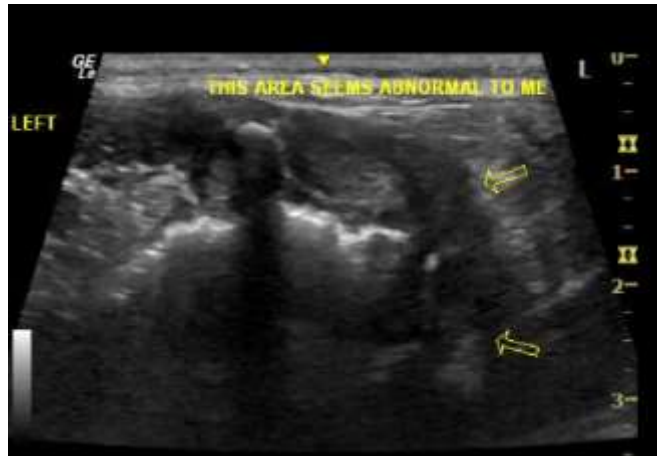
Dr. Park

INVOICE

49225

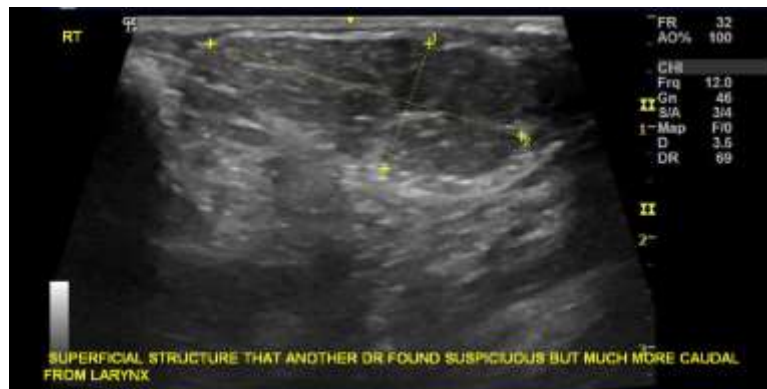DATE

12-23-21



Assuming this is the same area in longitudinal as the transverse depicted above, I agree. The central, crescent shaped line casts a shadow and thus represents air. The undulating, hyperechoic line dorsal and to either side of the shadow cast could represent the longitudinal gas shadow of the trachea. Otherwise, it could represent the caudal aspect of the pharynx with the tongue.

5)

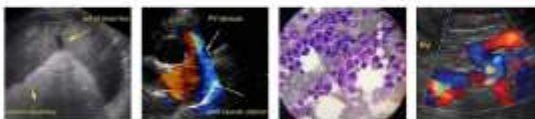


I feel this is a muscle

INTERPRETATION OF THE FINDINGS & FURTHER RECOMMENDATIONS

From the video clips provided, and assuming a transverse imaging plain, I felt that the laryngeal anatomy is physiological. The movement of the vocal cords I could not see. The region immediately caudal to the larynx (see 3) appears to be abnormal. Should this represent a tumor, it may contain air on one side. The differential diagnosis is a foreign body such as wood (4).

I suggest obtaining an ultrasound guided FNA, which can be done in the standing or sitting, unседated animal provided the respiratory movement does not interfere with the structure to be sampled. However, any type of treatment that may have to follow (surgery, or radiation) would require sedation or anesthesia which seems to be a problem in this patient.



PATIENT

Abby Davenport

SPECIES

Canine

The information and recommendations provided are based on the images presented by the referring veterinarian. No evaluation can be communicated regarding pathology that was not visible in the image/video clips provided.

BREED

Beagle

Thank you for this referral. If the clinical or image interpretation does not parallel your findings or if I can be of any further assistance please contact me.

Heike Rudolf, DVM, Dr. med. vet., DipECVDI, DVR
Dr.H.Rudorf@gmail.com

SEX

FS

AGE

11 Years

WEIGHT

26.8 lbs

INTERPRETED BY

Heike Rudolf, DVM, Dr.
med. Vet., DipECVDI DVR

IMAGING PERFORMED BY

Loetitia Saint-Jacques, RVT

HOSPITAL NAME

VCA Lakeside Animal
Hospital

REFERRING VET

Dr. Park

INVOICE

49225

DATE

12-23-21