

**PATIENT**

Elsa Scirica

PRESENTING CLINICAL SIGNS

Jumped off back of recliner, tail puffed up and took off down the hall, when cat came back out she was limping on the right hind leg

Abnormal PE/Chem/CBC/UA Results: Fractious cat. BCS 7/9. Awake exam is limited with cat more reactive to palpation of right hip and stifle. Following sedation right stifle is thickened and painful on palpation, no cranial drawer detected.

SPECIES

Feline

RADIOGRAPHIC STUDY OF THE STIFLES**BREED**

DSH

1x R lat. stifle, 1x VD abdomen including stifles, 3x VD pelvis including stifles,

RADIOGRAPHIC FINDINGS

Only six lumbar vertebrae are present.

SEX

Female Spayed

The R stifle joint has smooth subchondral bone surfaces. The centre of the femoral condyles appears to be located cranial to the intercondylar eminence. The cranial fat pad appears reduced distally by a soft tissue opacity within the joint. The caudal fascial plains are in a physiological position. New bone formation is not evident, and the patella is located in its groove. Calcification of the distal patella tendon is present.

AGE

7 Years, 3 Months

RADIOGRAPHIC DIAGNOSIS

- Calcification patella tendon
- Possible mild joint effusion
- Reduced number of lumbar vertebrae (incidental finding)

INTERPRETED BY

Heike Rudolf, DVM,
Dr. med. Vet.,
DipECVDI DVR

INTERPRETATION OF THE FINDINGS & FURTHER RECOMMENDATIONS

The changes described for the lateral stifle view could be the result of obliquity or could represent a mild effusion due to trauma (hemorrhage) or fiber disruption of the cruciate ligament with inflammatory effusion. Repeating the clinical examination in 7 days is recommended. The calcification of the patella tendon is likely of no significance.

HOSPITAL NAME

BLANDFORD
ANIMAL HOSPITAL,
INC

REFERRING VET

Amber Cull-Fournier

INVOICE

48723

DATE

12-2-21



PATIENT

Elsa Scirica

SPECIES

Feline

BREED

DSH

SEX

Female Spayed

AGE

7 Years, 3 Months

INTERPRETED BY

Heike Rudolf, DVM,
Dr. med. Vet.,
DipECVDDI DVR

HOSPITAL NAME

BLANDFORD
ANIMAL HOSPITAL,
INC

REFERRING VET

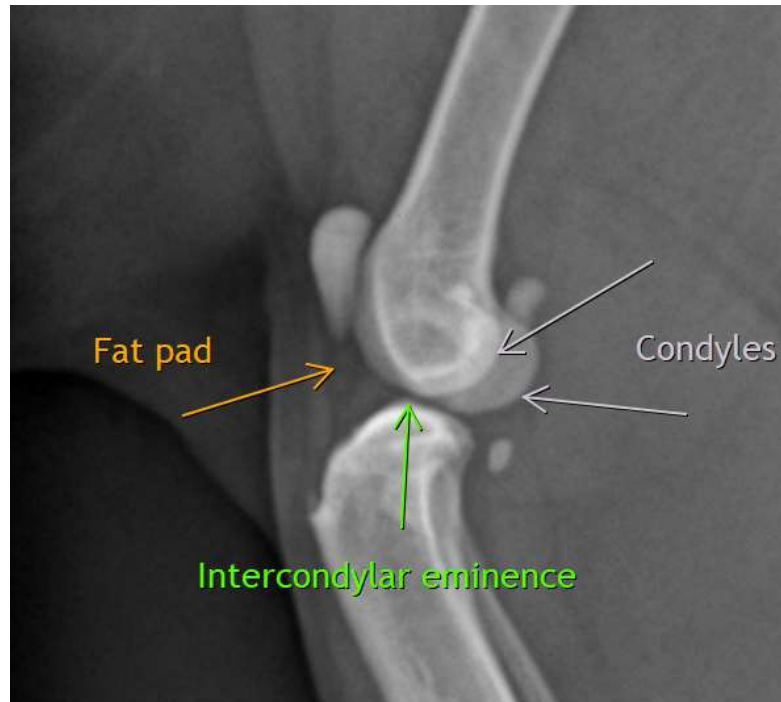
Amber Cull-Fournier

INVOICE

48723

DATE

12-2-21



The information and recommendations provided are based on the images presented by the referring veterinarian. No evaluation can be communicated regarding pathology that was not visible in the image/video clips provided.

Thank you for this referral. If the clinical or image interpretation does not parallel your findings or if I can be of any further assistance please contact me.

Heike Rudolf, DVM, Dr. med. vet., DipECVDDI, DVR
Dr.H.Rudorf@gmail.com