



PATIENT PRESENTING CLINICAL SIGNS

Buddy Nunez
SPECIES Dog has a recurrent hacking cough. Also wheezes on exhale. Treated for HW years ago. March 2021: gagging "like something in throat", mainly when lays down at night,HR 100, no murmur, sinus arrhythmia. treated with Baytril, Dex IM, Baytril PO. Did much better. 10-8-21 : hacking again, HR 100, sinus arrhythmia. treated with Tem-P, no change, no better. Seen 11-30-21, HR 120, no murmur, sinus arrhythmia. Treated with Baytril IM, Dex IM, Baytril PO, Pred 5 mg SID PO, owner says cough is 90% better!
Canine Abnormal PE/Chem/CBC/UA Results: Chem: ALP: 800, all else WNL, overweight.

BREED RADIOGRAPHIC STUDY OF THE THORAX

Jack Russell 1x LLR and 1x DV

RADIOGRAPHIC FINDINGS

SEX The body condition score is 7/9 with smooth alternating layers of fat and soft tissue opacity.

MN The bony structures appear physiological.

AGE The degree of pulmonary expansion is fair at best. The lungs are in contact with the thoracic boundaries and the tips are pointed. The lobar vessels are just visible on a black background.

8+ Years The cranial mediastinum is of physiological size and opacity. The trachea runs parallel to the thoracic vertebrae and dips at the carina.

INTERPRETED BY

Heike Rudolf, DVM, Dr. med. Vet., DipECVDI DVR The cardiac silhouette occupies 85% of the chest height and 3.25 intercostal spaces. The main stem bronchi are laterally displaced, suggesting left atrial (LA) enlargement.

RADIOGRAPHIC DIAGNOSIS

- Suggestion of tracheal collapse
- Possible left atrial enlargement

HOSPITAL NAME

Maheer Animal Hospital

INTERPRETATION OF THE FINDINGS & FURTHER RECOMMENDATIONS

REFERRING VET

Katie Maher

Tracheal collapse alone can be due to a weakened dorsal tracheal ligament. Tracheal in combination with bronchial collapse is usually caused by chondromalacia and is thus due to an altered cartilage development which may go unnoticed until physical circumstances (such as stress, running, excitement) or disease (e.g. pneumonia, bronchitis, L cardiac enlargement) reduces the ease of airflow. Echocardiography to assess mitral valve and L atrial size as well as bronchoscopy to obtain a BAL is recommended. Should an underlying disease be present treatment may improve the clinical signs.

INVOICE

48724

Obesity is known to worsen clinical signs of cough and impair lung function; weight control is strongly recommended.

DATE

12-2-21

TECHNICAL COMMENTS

Only jpg images were submitted. The transformation from DICOM to jpg reduces the image



PATIENT

Buddy Nunez

quality (here by increasing the graininess) and only allows limited manipulation of the image. More subtle lesions can thus easily be missed. For the best possible imaging reports, I suggest submitting DICOM images in the future.

SPECIES

Canine

BREED

Jack Russell

SEX

MN

AGE

8+ Years

INTERPRETED BY

Heike Rudorf, DVM,
Dr. med. Vet.,
DipECVDI DVR

HOSPITAL NAME

Maher Animal
Hospital

REFERRING VET

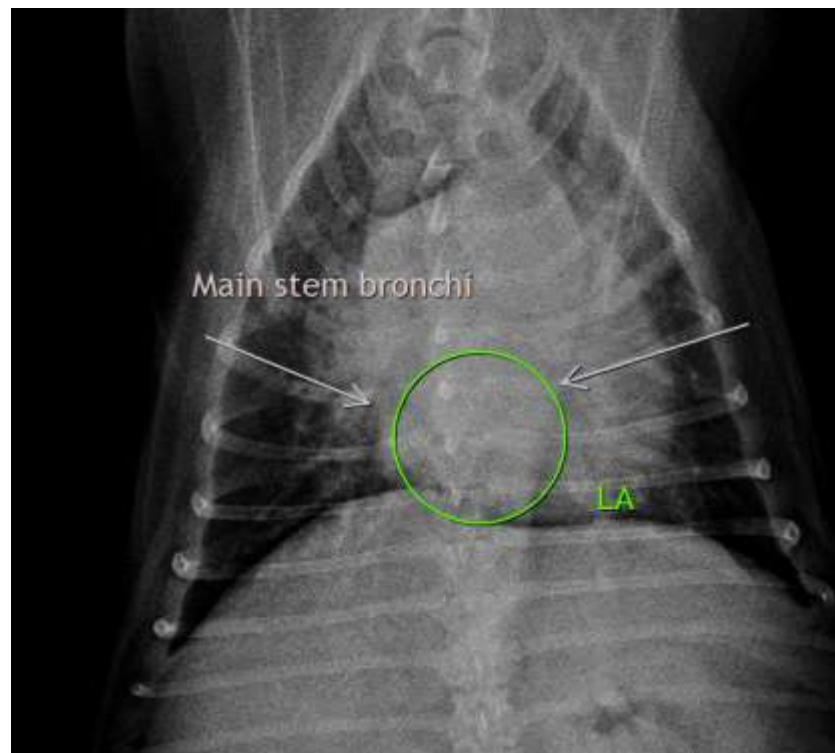
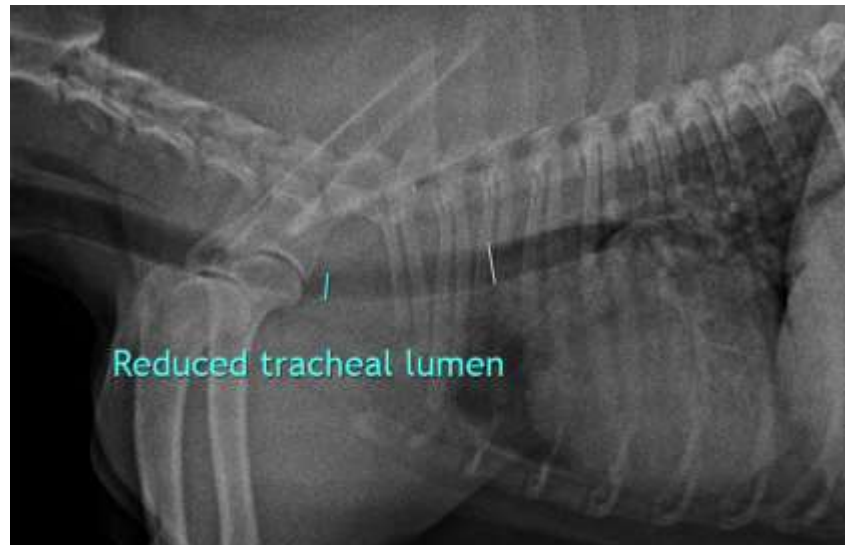
Katie Maher

INVOICE

48724

DATE

12-2-21





PATIENT

Buddy Nunez

SPECIES

Canine

BREED

Jack Russell

SEX

MN

AGE

8+ Years

INTERPRETED BY

Heike Rudolf, DVM,
Dr. med. Vet.,
DipECVDI DVR

HOSPITAL NAME

Maher Animal
Hospital

REFERRING VET

Katie Maher

INVOICE

48724

DATE

12-2-21

The information and recommendations provided are based on the images presented by the referring veterinarian. No evaluation can be communicated regarding pathology that was not visible in the image/video clips provided.

Thank you for this referral. If the clinical or image interpretation does not parallel your findings or if I can be of any further assistance please contact me.

Heike Rudolf, DVM, Dr. med. vet., DipECVDI, DVR
Dr.H.Rudorf@gmail.com