



## PATIENT

Stanley McNamara

## SPECIES

Canine

## BREED

Pitbull Mix

## SEX

Neutered Male

## AGE

10 Years

## WEIGHT

93.2

## INTERPRETED BY

Heike Rudolf, DVM, Dr.  
med. Vet., DipECVDI  
DVR

## IMAGING PERFORMED BY

Dr. Stanton

## HOSPITAL NAME

Long Valley AH

## REFERRING VET

Dr. Stanton

## INVOICE

36000

## DATE

12/19/25

## PRESENTING CLINICAL SIGNS

History: Follow up rads - history of 5cm mass in R caudal lung lobe- pulmonary adenocarcinoma. Thoracotomy performed 6/13/25, fully excised with clear margins. Ultrasound preformed 6/3/25 & CT preformed 6/6/25 by SonoPath.

## RADIOGRAPHIC STUDY OF THE THORAX

The body condition score is 7/9 with smooth, alternating layers of fat and soft tissue opacity.

A small amount of spondylosis is present ventral to T9/10.

The cranial mediastinum is of physiologic width and opacity. The terminal trachea diverges from the thoracic vertebrae and dips at the carina. An ill defined, roundish soft tissue opacity is located dorsal to the bifurcation in right lateral recumbency.

One set of blood vessels is superimposed onto the right crus of the diaphragm in right lateral recumbency. The right crus is slightly further cranial located on the DV. The lung lobes are well aerated and extend to the thoracic boundaries. Pulmonary vessels are well outlined on the left and difficult to see on the right.

The cardiac silhouette occupies 75% of the chest height and 2.5 intercostal spaces. Chamber or outflow tract enlargement is not obvious.

## RADIOGRAPHIC DIAGNOSIS

- R caudal lobe absent
- Soft tissue opacity hilar region

## Incidental finding

- Spondylosis

## INTERPRETATION OF THE FINDINGS & FURTHER RECOMMENDATIONS

I can see no pulmonary nodules. The roundish structure described in right lateral recumbency could represent a composite shadow at the place of lobar resection or may be caused by bronchial lymph node enlargement. Follow up studies in approx. 4 weeks are recommended. In case of lymph node enlargement, I would expect it to have increased in size.



## PATIENT

Stanley McNamara

## SPECIES

Canine

## BREED

Pitbull Mix

## SEX

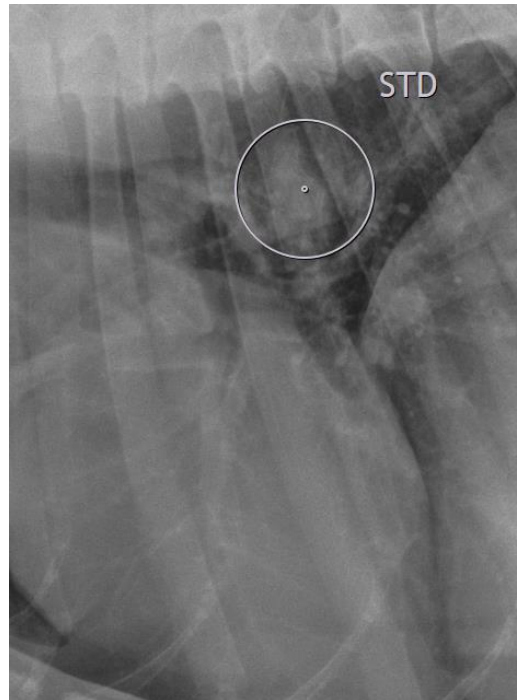
Neutered Male

## AGE

10 Years

## WEIGHT

93.2



## INTERPRETED BY

Heike Rudolf, DVM, Dr.  
med. Vet., DipECVDI  
DVR

## IMAGING PERFORMED BY

Dr. Stanton

## HOSPITAL NAME

Long Valley AH

## REFERRING VET

Dr. Stanton

## INVOICE

36000

## DATE

12/19/25

The information and recommendations provided are based on the images presented by the referring veterinarian/sonographer. No evaluation can be communicated regarding pathology that was not visible in the image/video clips provided.

Thank you for this referral. If the clinical or image interpretation does not parallel your findings or if I can be of any further assistance, please contact me.

Heike Rudolf, DVM, Dr. med. vet., DipECVDI, DVR  
[info@sonopath.com](mailto:info@sonopath.com)