
PATIENT PRESENTING CLINICAL SIGNS

River Sangster
 Sudden onset of anorexia , general weakness and icterus , losing weight
 Abnormal PE/Chem/CBC/UA Results: BCS=4/9, moderate abdominal pain , moderate hind leg weakness& muscle atrophy , MM; severely icteric , bloodwork indicated : sever neutrophilic leukocytosis lymphopenia Eosinopenia, mild thrombocytopenia , elevated Phosphorus, hyperglycemia , ALP, GGT, T. bilirubin , decreased protein , Albumin , Na, K, Cl, sever elevation of CPLl, negative leptospirosis in-house test , negative 4DX.

SPECIES

Canine

RADIOGRAPHIC STUDY OF THE ABDOMEN
BREED

1x

Retriever Chesapeake Bay

RADIOGRAPHIC FINDINGS

The body condition score is 5/9 with a distended abdomen.

SEX

A small amount of spondylosis is present.

Female

The abdominal detail is generally reduced due to a striated appearance making assessment of the abdominal organs difficult. The included dorsal lung lobes are retracted from the vertebral column.

AGE

The tail of the spleen appears small.

10 Years

Bilateral pleural fluid is present on the DV view of the thorax.

INTERPRETED BY

 Heike Rudolf, DVM,
 Dr. med. Vet.,
 DipECVDI DVR

RADIOGRAPHIC DIAGNOSIS

- Pleural fluid
- Ascites

INTERPRETATION OF THE FINDINGS & FURTHER RECOMMENDATIONS
HOSPITAL NAME

St. Catharine's AH

The two types of fluid may be different which would indicate two different disease processes. The reduced abdominal detail could be the result of inflammation, infection, blood, bile and urine. Sever pancreatitis and rupture of the biliary system (e.g. gall bladder or bile duct) are possible causes. Abdominal ultrasound is strongly recommended. A sample of the abdominal as well as the thoracic fluid should be obtained.

REFERRING VET

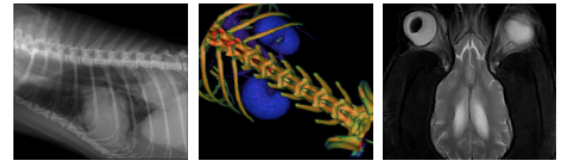
Dr. Masoud

INVOICE

33536

DATE

12/17/21



PATIENT

River Sangster

SPECIES

Canine

BREED

Retriever Chesapeake Bay

SEX

Female

AGE

10 Years

INTERPRETED BY

Heike Rudorf, DVM,
Dr. med. Vet.,
DipECVDI DVR

HOSPITAL NAME

St. Catharine's AH

REFERRING VET

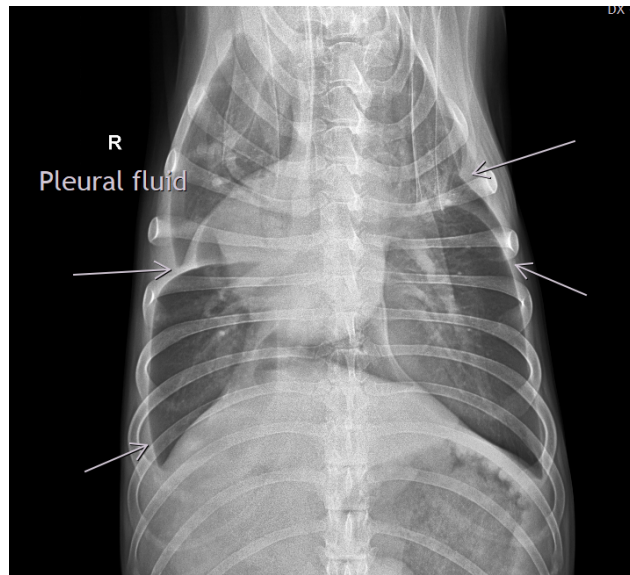
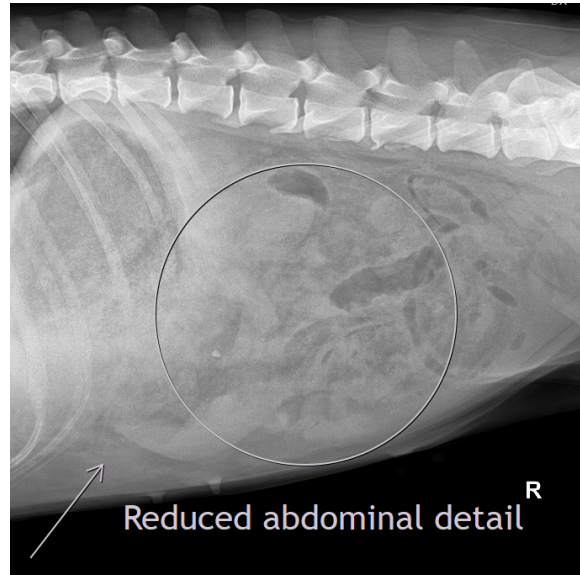
Dr. Masoud

INVOICE

33536

DATE

12/17/21



The information and recommendations provided are based on the images presented by the referring veterinarian. No evaluation can be communicated regarding pathology that was not visible in the image/video clips provided.

Thank you for this referral. If the clinical or image interpretation does not parallel your findings or if I can be of any further assistance please contact me.

Heike Rudorf, DVM, Dr. med. vet., DipECVDI, DVR
dr.h.rudorf@gmail.com