



PATIENT PRESENTING CLINICAL SIGNS

Oliver MacBean History: 7 weeks old puppy was presented with sudden onset of lethargy and trembling , owner reported that heart has stopped for few seconds, then has started again
Abnormal PE/Chem/CBC/UA Results: Low creatine mild elevation of ALP , Ca , Ph

SPECIES RADIOGRAPHIC STUDY OF THE THORAX

Canine

The body condition score is 5/9 with smooth alternating layers of fat and soft tissue opacity.
The open growth plates and missing calcification of the costal cartilages indicate a dog younger than 3 months of age.

BREED

Bichon Frise

The lungs are in contact with the thoracic boundaries and the tips are pointed. The lobar vessels are clearly visible to the tertiary branches. The bronchial tree is thin walled and tapers uniformly towards the periphery.

SEX

Male

The cranial mediastinum is of physiological size and opacity. The trachea diverges from the thoracic vertebrae and the carina is located at T5.

AGE

12 Weeks

The cardiac silhouette occupies 75% of the chest height and 3.5 intercostal spaces (VHS 10). No obvious chamber or outflow tract enlargement is evident. The pulmonary vessels have a physiological size.
The liver is located within the costal arch and the gastric axis appears to be rotated cranially on the left lateral recumbent view.

INTERPRETED BY RADIOGRAPHIC DIAGNOSIS

Heike Rudolf, DVM,
Dr. med. Vet.,
DipECVDI DVR

- I can see no explanation in the thorax for the described clinical signs

HOSPITAL NAME INTERPRETATION OF THE FINDINGS & FURTHER RECOMMENDATIONS

St. Catharine's AH

The liver appears to be small and ultrasound to rule out a PSS could be performed. Alternatively, pre- and post-prandial bile acids can be measured.

REFERRING VET

Dr. Boctor

INVOICE

13099

DATE

12/17/21



PATIENT

Oliver MacBean

SPECIES

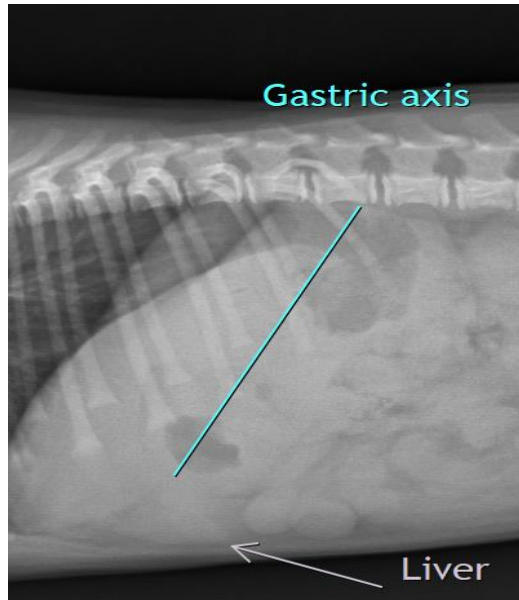
Canine

BREED

Bichon Frise

SEX

Male



AGE

12 Weeks

The information and recommendations provided are based on the images presented by the referring veterinarian. No evaluation can be communicated regarding pathology that was not visible in the image/video clips provided.

Thank you for this referral. If the clinical or image interpretation does not parallel your findings or if I can be of any further assistance please contact me.

INTERPRETED BY

Heike Rudolf, DVM,
Dr. med. Vet.,
DipECVDI DVR

Heike Rudolf, DVM, Dr. med. vet., DipECVDI, DVR
dr.h.rudorf@gmail.com

HOSPITAL NAME

St. Catharine's AH

REFERRING VET

Dr. Boctor

INVOICE

13099

DATE

12/17/21