



PATIENT

Tate Stapp

PRESENTING CLINICAL SIGNS

Patent has had a history for the past week of walking with more weight on the lateral digit of the R thoracic limb. In the past 48 hours, he's been consistently lame on this limb. On exam, he does bear most of his weight on the lateral digits so that digits 1 and 2 are almost raised off the floor. There is no pain on ROM of carpi, palpation of the long bone/elbows, or shoulder extension.

SPECIES

Canine

RADIOGRAPH OF ELBOWS AND CARPI

Lateral distal limb L and R straight and flexed, DP both distal limbs, lateral both shoulders, 2x VD both upper fore limbs

BREED

Cane Corso

RADIOGRAPHIC FINDINGS

The skin surfaces are smooth, and the muscles appear to be symmetrically developed.

SEX

M

Skeletal immaturity compatible with the given age is noted. Growth plate size is symmetric.

The bones are well mineralized, have a normal trabecular structure and smooth, continuous surfaces. Cortical-medullary development and differentiation of the long bones are physiological.

AGE

11 Weeks

The elbow joints appear to be congruent with smooth subchondral bone surfaces. The line separating the two condyles is visible on the right.

The P1/2 joints are flexed on one leg in the DP view.

INTERPRETED BY

Heike Rudorf, DVM,
Dr. med. Vet.,
DipECVDDVR

RADIOGRAPHIC DIAGNOSIS

- Flexed P1/2 joints on one side

HOSPITAL NAME

Bergen County
Veterinary Center

INTERPRETATION OF THE FINDINGS & FURTHER RECOMMENDATIONS

The flexion of the distal toes could be a positional artefact or may be related to contraction of the flexor tendon. I can see no bony reason for the abnormal gait. Possible causes for the abnormal gait include tendinitis, foreign body, joint capsule distension. I suggest examining each digit separately and comparing the response of the animal to the contralateral side. Depending on the location of the pain, cross sectional imaging or ultrasound could be employed as further diagnostic tests.

REFERRING VET

Deirdre Halloran

TECHNICAL COMMENTS

INVOICE

No side marker on DP paw view

48941

DATE

12-10-21



PATIENT

Tate Stapp

SPECIES

Canine

BREED

Cane Corso

SEX

M

AGE

11 Weeks

INTERPRETED BY

Heike Rudorf, DVM,
Dr. med. Vet.,
DipECVDDI DVR

HOSPITAL NAME

Bergen County
Veterinary Center

REFERRING VET

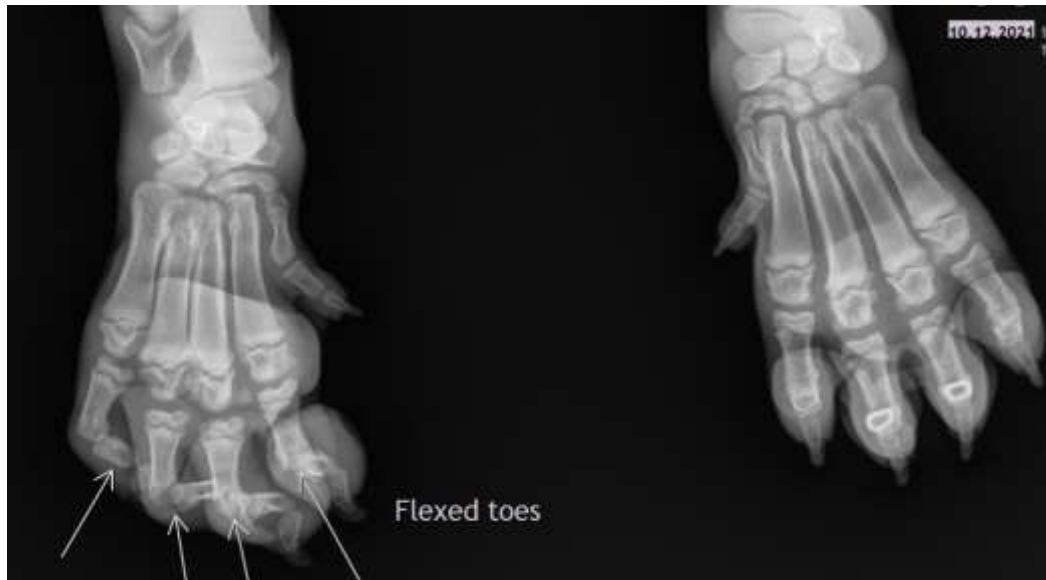
Deirdre Halloran

INVOICE

48941

DATE

12-10-21



The information and recommendations provided are based on the images presented by the referring veterinarian. No evaluation can be communicated regarding pathology that was not visible in the image/video clips provided.

Thank you for this referral. If the clinical or image interpretation does not parallel your findings or if I can be of any further assistance please contact me.

Heike Rudorf, DVM, Dr. med. vet., DipECVDDI, DVR
Dr.H.Rudorf@gmail.com