



PATIENT

Sue Duclon

PRESENTING CLINICAL SIGNS

Soft, green stool yesterday, lethargic and not eating well at all since.
 Abnormal PE/Chem/CBC/UA Results: PE: Tense abdomen, quiet acting, mild ptyalism.
 Abdominal ultrasound pending.

SPECIES

Canine

RADIOGRAPH OF THE ABDOMEN

RLR, LLR, VD

BREED

Red Heeler

RADIOGRAPHIC FINDINGS

The body condition score is 4/9 with little abdominal fat.

SEX

FS

The visible facet of T13 and L1 show a separate, crescent shaped bone cap. The region of the former physal lines are still slightly more lucent than the rest.

The liver is located within the costal arch and the caudo-ventral lobe is pointed.

The spleen is slightly large and follows the ventral abdominal wall to terminate level with L5.

AGE

1 Year, 2 Months

The stomach is moderately full and contains a mixture of fluid, air and striated, soft tissue material. The small intestinal loops have a physiological distribution and size and vary in contents so that they contain no gas on the VD and gas in two stacked loops on the left lateral recumbent view. Colon and rectum contain a moderate amount of unformed fecal matter; the descending colon is located in the ventral abdomen. The shape of the cecum is not symmetric on the VD view and the ileum appears to contain some gas as well.

Both renal shadows are not clearly outlined. The bladder is located in the abdominal cavity and contains a moderate amount of homogeneous fluid opacity.

The sublumbar region appears physiological.

INTERPRETED BY

Heike Rudolf, DVM,
 Dr. med. Vet.,
 DipECVDI DVR

RADIOGRAPHIC DIAGNOSIS

- Variable, mild intestinal distension
- Unusual size and shape of the cecum
- Splenomegaly, mild

HOSPITAL NAME

Elizabeth Animal
 Hospital

INTERPRETATION OF THE FINDINGS & FURTHER RECOMMENDATIONS

I can see no radiopaque foreign object. The planned ultrasound examination should help rule out a soft tissue foreign body and inflammation of the cecum. The slightly big spleen is probably physiological for the breed.

REFERRING VET

Leon Anderson, DVM

INVOICE

48944

DATE

12-10-21



PATIENT

Sue Duclon

SPECIES

Canine

BREED

Red Heeler

SEX

FS

AGE

1 Year, 2 Months

INTERPRETED BY

Heike Rudolf, DVM,
Dr. med. Vet.,
DipECVDI DVR

HOSPITAL NAME

Elizabeth Animal
Hospital

REFERRING VET

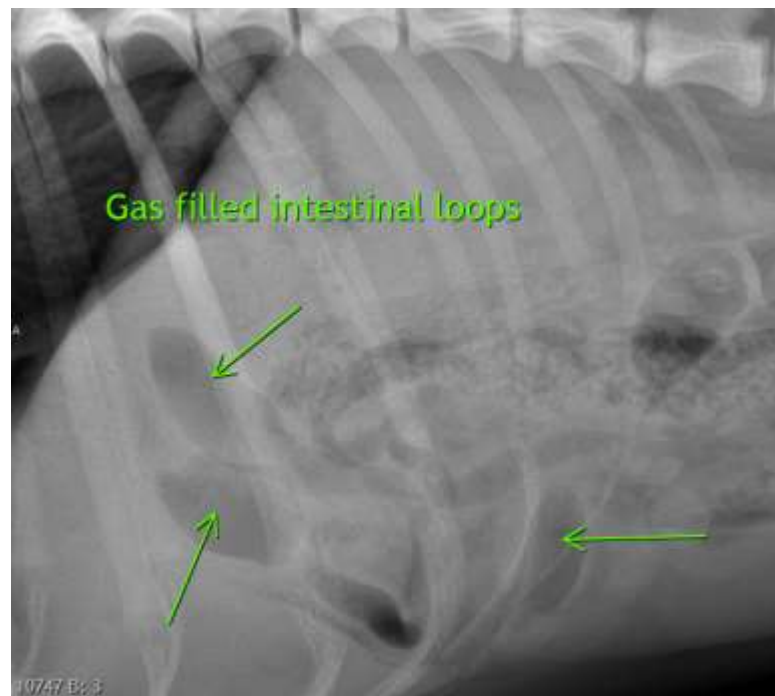
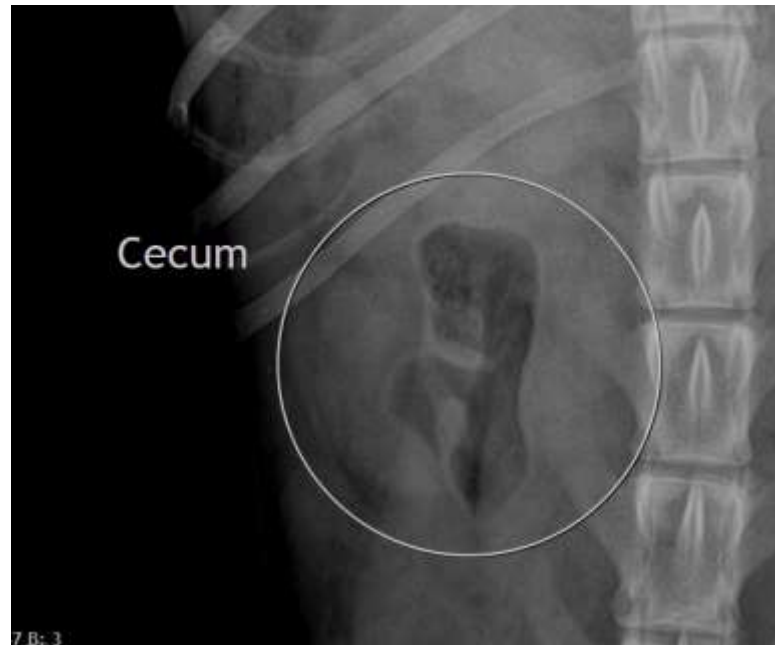Leon Anderson, DVM

INVOICE

48944

DATE

12-10-21





PATIENT

Sue Duclon

The information and recommendations provided are based on the images presented by the referring veterinarian. No evaluation can be communicated regarding pathology that was not visible in the image/video clips provided.

SPECIES

Canine

Thank you for this referral. If the clinical or image interpretation does not parallel your findings or if I can be of any further assistance please contact me.

BREED

Red Heeler

Heike Rudorf, DVM, Dr. med. vet., DipECVDI, DVR
Dr.H.Rudorf@gmail.com

SEX

FS

AGE

1 Year, 2 Months

INTERPRETED BY

Heike Rudorf, DVM,
Dr. med. Vet.,
DipECVDI DVR

HOSPITAL NAME

Elizabeth Animal
Hospital

REFERRING VET

Leon Anderson, DVM

INVOICE

48944

DATE

12-10-21