



PATIENT

SNOWFLAKE PUPO-BASSFORD

PRESENTING CLINICAL SIGNS

Follow up from VCA last night - vomit episode(s) three times (1st two was food) (3rd Pepto)
 Owner concerned about foreign body_ likes to get into the trash cans (toilet paper)
 Physical Examination Key -- Oral cavity:Mild dental tartar Musculoskeletal: BCS = 6/9.
 Ambulatory x 4. Grade 2/4 L MPL, Grade 2-3/4 R MPL w/ moderate crepitus Hydration: < 5% dehydration

SPECIES

Canine

RADIOGRAPH OF THE ABDOMEN

RLR, LLR, VD

BREED

Maltese

RADIOGRAPHIC FINDINGS

The body condition score is 7/9 with smoothly alternating layers of fat dorsal to the spinous processes.

SEX

Spayed Female

The bony structures are within normal limits.

The abdominal detail is good; diaphragm and abdominal wall are intact.

AGE

5 Years, 1 Month

The liver is located within the costal arch and the caudo-ventral lobe is pointed.

The spleen appears physiological.

INTERPRETED BY

Heike Rudolf, DVM,
 Dr. med. Vet.,
 DipECVDI DVR

The stomach contains a large amount of fluid with a gas cap. In left lateral recumbency the pylorus appears physiological, and the duodenum is slightly distended with air; this is not present on the other views. Colon and rectum contain a mixture of formed fecal matter and gas.

Both renal shadows have a physiological size, shape and opacity; the surfaces are smooth. The bladder is located in the abdominal cavity and contains a moderate amount of homogeneous fluid opacity.

HOSPITAL NAME

DPC Veterinary Hospital

The sublumbar region appears physiological.

RADIOGRAPHIC DIAGNOSIS

- Fluid distended stomach, moderate

REFERRING VET

Dr. Rivera

INTERPRETATION OF THE FINDINGS & FURTHER RECOMMENDATIONS

I can see no radiopaque foreign body or ileus. However, paper would not be visible radiographically thus ultrasound is recommended should the clinical signs persist or reoccur after medical treatment is stopped. A cPLI test should be carried out and amylase examined if it has not already been done.

INVOICE

48942

DATE

12-10-21



PATIENT

SNOWFLAKE PUPO-
BASSFORD

SPECIES

Canine

BREED

Maltese

SEX

Spayed Female

AGE

5 Years, 1 Month

INTERPRETED BY

Heike Rudolf, DVM,
Dr. med. Vet.,
DipECVDI DVR

HOSPITAL NAME

DPC Veterinary
Hospital

REFERRING VET

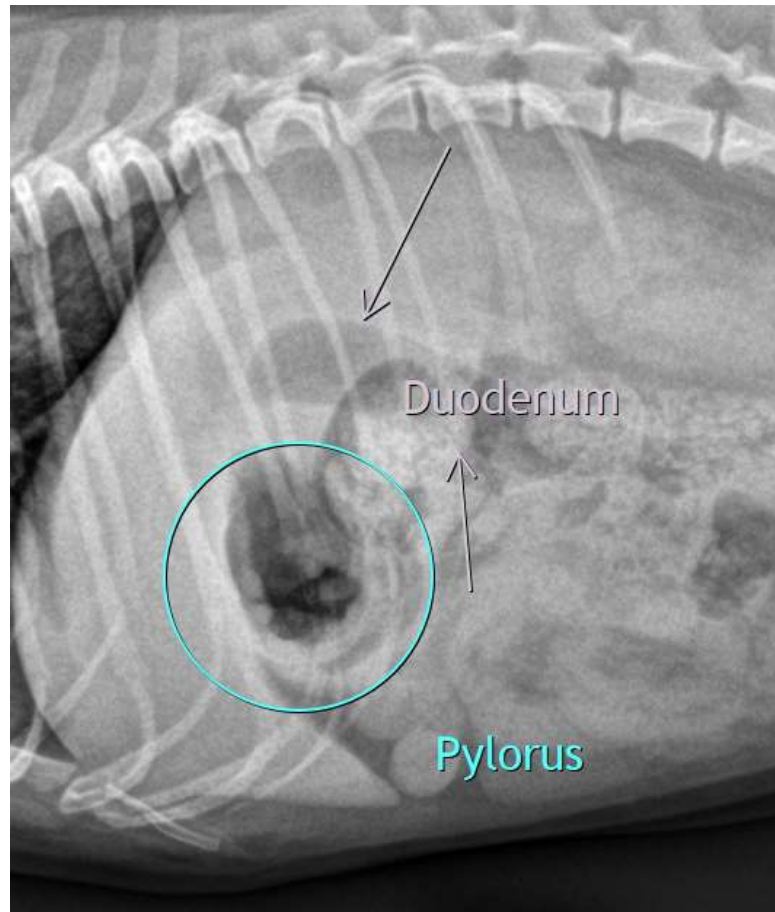
Dr. Rivera

INVOICE

48942

DATE

12-10-21



The information and recommendations provided are based on the images presented by the referring veterinarian. No evaluation can be communicated regarding pathology that was not visible in the image/video clips provided.

Thank you for this referral. If the clinical or image interpretation does not parallel your findings or if I can be of any further assistance please contact me.

Heike Rudolf, DVM, Dr. med. vet., DipECVDI, DVR
Dr.H.Rudorf@gmail.com