



PATIENT PRESENTING CLINICAL SIGNS

Winston Kallert History: eval thorax for neuter - pre sx eval

RADIOGRAPHIC STUDY OF THE THORAX

SPECIES The body condition score is 6/9 with smooth alternating layers of fat and soft tissue opacity.

Canine The bony structures appear physiological.

BREED The lungs are in contact with the thoracic boundaries and the tips are pointed. The lobar vessels are clearly visible to the tertiary branches. The bronchial tree is thin walled and tapers uniformly towards the periphery.

English Bulldog The cranial mediastinum is of physiological size and opacity. The trachea diverges from the thoracic vertebrae and dips at the carina.

SEX The cardiac silhouette occupies 75% of the chest height and 3.5 intercostal spaces. No chamber or outflow tract enlargement is evident. On the VD view the caudal vena cava appears blurred but normal on the lateral views.

Male

RADIOGRAPHIC DIAGNOSIS

- Physiological study

1 Year

INTERPRETATION OF THE FINDINGS & FURTHER RECOMMENDATIONS

INTERPRETED BY I can see no changes that would interfere with the surgery. However, should dyspnea or cough be present, bronchitis will have to be ruled out with the aid of bronchoscopy and BAL because peribronchial infiltrate can be present without radiographic evidence.

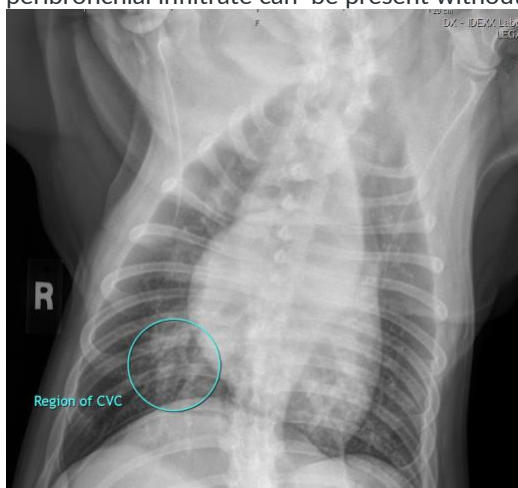
Heike Rudorf, DVM,
Dr. med. Vet.,
DipECVDI DVR

HOSPITAL NAME

Legacy AH

REFERRING VET

Dr. Kristin Potenzzone,
DVM



INVOICE

18961

The information and recommendations provided are based on the images presented by the referring veterinarian/sonographer. No evaluation can be communicated regarding pathology that was not visible in the image/video clips provided.

DATE

12/1/22



PATIENT

Winston Kallert

Thank you for this referral. If the clinical or image interpretation does not parallel your findings or if I can be of any further assistance please contact me.

SPECIES

Canine

Heike Rudorf, DVM, Dr. med. vet., DipECVDI, DVR
dr.h.rudorf@gmail.com

BREED

English Bulldog

SEX

Male

AGE

1 Year

INTERPRETED BY

Heike Rudorf, DVM,
Dr. med. Vet.,
DipECVDI DVR

HOSPITAL NAME

Legacy AH

REFERRING VET

Dr. Kristin Potenzzone,
DVM

INVOICE

18961

DATE

12/1/22