



PATIENT PRESENTING CLINICAL SIGNS

Shayna Satnick History: Weight gain, grossly overweight
Abnormal PE/Chem/CBC/UA Results: thyroid panel pending and diet change

SPECIES RADIOGRAPHIC STUDY OF THE ABDOMEN

Canine A large amount of dorsal subcutaneous fat is present.
Eight lumbar vertebrae are present.

BREED The abdominal detail is good; the ventral abdominal wall is slightly pendulous.

Maltipoo The ventral liver lobe is extending just beyond the costal arch and is rounded.

SEX The spleen appears physiological.

Spayed Female The stomach contains a moderate amount of food; distribution and size of the small intestinal loops appear physiological. Colon and rectum contain a moderate amount of unformed fecal matter.

AGE The region of the kidneys appears physiological. The bladder shadow is small.

3 Years The sublumbar region appears physiological.

RADIOGRAPHIC DIAGNOSIS

INTERPRETED BY

Heike Rudorf, DVM,
Dr. med. Vet.,
DipECVDI DVR

- Large amount of dorsal s.c. fat
- Food in stomach
- Mild hepatomegaly
- Supernumerous lumbar vertebra (incidental finding)

INTERPRETATION OF THE FINDINGS & FURTHER RECOMMENDATIONS

HOSPITAL NAME

New Bridge VP

The distribution of fat could indicate Cushing's disease. The slight rounding of the caudal liver lobe could be due to fatty infiltrate which accompanies Cushing's disease as well as Diabetes mellitus. I thus advise ruling out these two diseases as well as hypothyroidism. However, the age of the dog suggests a discrepancy of exercise and intake of calories.

REFERRING VET

Dr. Abina Glennon

INVOICE

18959

DATE

12/1/22



PATIENT

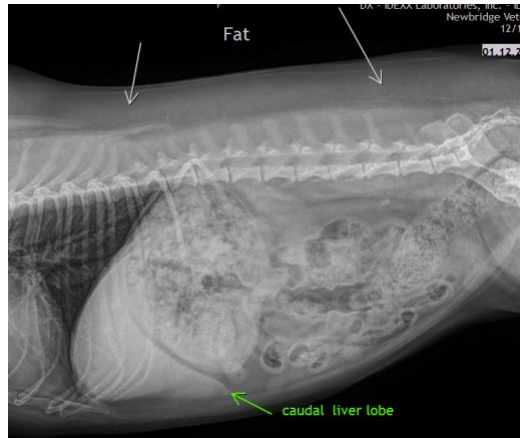
Shayna Satnick

SPECIES

Canine

BREED

Maltipoo



SEX

Spayed Female

AGE

3 Years

The information and recommendations provided are based on the images presented by the referring veterinarian/sonographer. No evaluation can be communicated regarding pathology that was not visible in the image/video clips provided.

Thank you for this referral. If the clinical or image interpretation does not parallel your findings or if I can be of any further assistance please contact me.

Heike Rudorf, DVM, Dr. med. vet., DipECVDI, DVR
dr.h.rudorf@gmail.com

INTERPRETED BY

Heike Rudorf, DVM,
Dr. med. Vet.,
DipECVDI DVR

HOSPITAL NAME

New Bridge VP

REFERRING VET

Dr. Abina Glennon

INVOICE

18959

DATE

12/1/22