



PATIENT PRESENTING CLINICAL SIGNS

Baxter Cocanower History: Intermittent lameness on RH over the last 3 weeks. Minimal response to NSAID therapy, gabapentin. No known trauma. Travel history is limited to NM and TX.

SPECIES Abnormal PE/Chem/CBC/UA Results: Weight bearing lameness on RH. Pain on palpation surrounding stifle. No instability on cranial drawer and patella remains reduced. Fungal serology is pending.

Canine RADIOGRAPHIC STUDY OF THE STIFLES

BREED Reduction of the muscle mass is present on the right leg. The distal third of the right femur shows destruction of the cortices with mild displacement of small fragments. The medullary cavity shows an approx. 7.5cm long patchy increase in opacity. A peanut shaped bony lump of periosteal new bone is located distal to the Codeman’s triangle on the medial surface of the altered cortical bone. The popliteal lymph node is slightly larger than on the left (1.8 vs 1.5cm).

Red Bone Hound

SEX RADIOGRAPHIC DIAGNOSIS

Neutered Male R femur

- Monostotic bone tumour
- Muscle atrophy
- Lymphadenomegaly, mild

AGE INTERPRETATION OF THE FINDINGS & FURTHER RECOMMENDATIONS

5 Years

INTERPRETED BY

Changes and their location are highly suggestive of an osteosarcoma. Fibrosarcoma and lymphoma are less likely differential diagnoses. For an accurate diagnosis a sample should be obtained. An ultrasound guided FNA of the region with the cortical destruction should be obtained because a Tru cut, full thickness bone biopsy could result in fracture. Samples of the popliteal lymph node may already reveal neoplastic cells. CT of the lungs or 3 inflated views of the thorax are recommended to look for metastases. Ultrasound of the abdominal lymph nodes, especially the sacral, hypogastric and iliac lymph nodes should be carried out.

**Heike Rudolf, DVM,
Dr. med. Vet.,
DipECVDI DVR**

HOSPITAL NAME

Ruidoso AC

REFERRING VET

Sarah Botkin

INVOICE

18933

DATE

12/1/22



PATIENT

Baxter Cocanower

SPECIES

Canine

BREED

Red Bone Hound

SEX

Neutered Male

AGE

5 Years

INTERPRETED BY

Heike Rudorf, DVM,
Dr. med. Vet.,
DipECVDI DVR

HOSPITAL NAME

Ruidoso AC

REFERRING VET

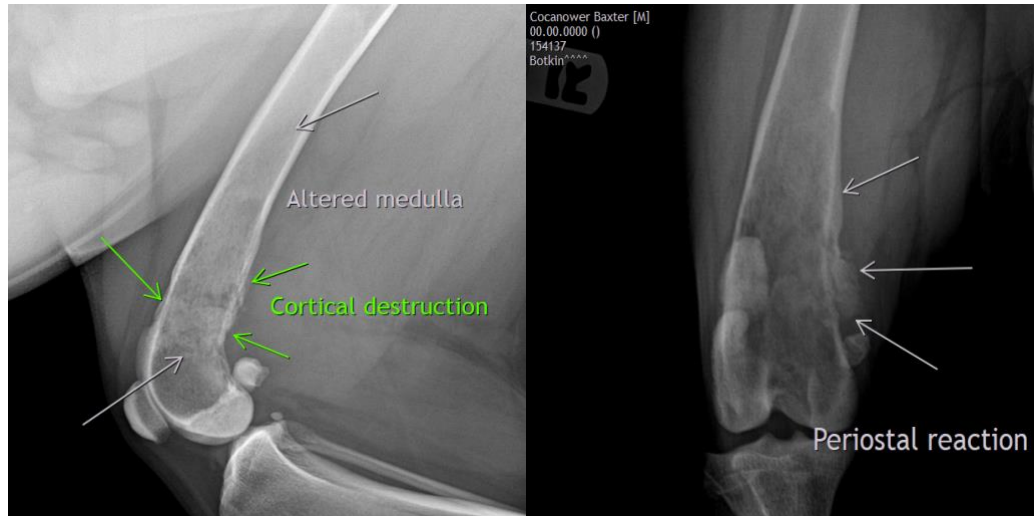
Sarah Botkin

INVOICE

18933

DATE

12/1/22



The information and recommendations provided are based on the images presented by the referring veterinarian/sonographer. No evaluation can be communicated regarding pathology that was not visible in the image/video clips provided.

Thank you for this referral. If the clinical or image interpretation does not parallel your findings or if I can be of any further assistance please contact me.

Heike Rudorf, DVM, Dr. med. vet., DipECVDI, DVR
dr.h.rudorf@gmail.com