



PATIENT

Eric Johnson

SPECIES

Feline

BREED

DSH

SEX

Neutered Male

AGE

14 Years

WEIGHT

4.6 kg

INTERPRETED BY

Heike Rudorf, DVM, Dr.
med. Vet., DipECVDF
DVR

IMAGING PERFORMED BY

Dr. Sherry Vartanian

HOSPITAL NAME

Green Dog Dental &
Wellness

REFERRING VET

Dr. Sherry Vartanian

INVOICE

35442

DATE

11/7/25

PRESENTING CLINICAL SIGNS

History: O requests house call for radiographs and updating vaccines/ labs. O states that P has not been able to jump up on the counter or other high surfaces recently and she wonders if he is in pain. Otherwise, P is eating and drinking well. No vomiting or diarrhea (except for a very occasional vomit - last one was over a month ago).

RADIOGRAPHIC STUDY OF THE PELVIS

LS spine: the disc space is narrow and ventral spondylosis is present. The right transverse process of L6 and L7 contain one or more circular lucencies with a thin sclerotic margin.

Pelvis: surrounding soft tissue structures of the pelvis are within normal limits. Both coxo-femoral joints are incongruent and a moderate amount of smooth new bone formation is located on the cranial acetabular edges. Sclerosis is present along the femoral necks.

RADIOGRAPHIC DIAGNOSIS

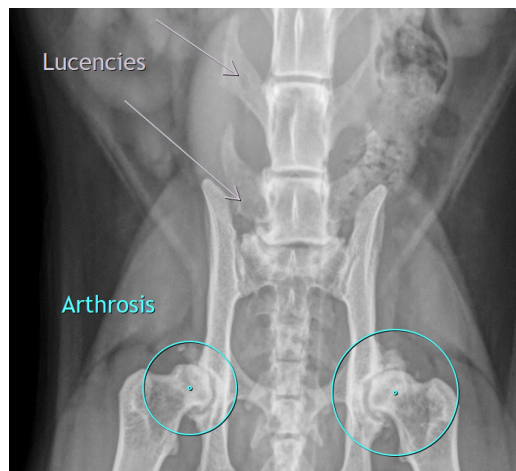
- Hip arthrosis bilateral, moderate

LS-junction

- Disc space narrowing
- Spondylosis
- Possible cysts transverse processes

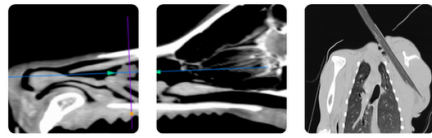
INTERPRETATION OF THE FINDINGS & FURTHER RECOMMENDATIONS

The changes on the LS junction could be associated with disc disease. In case the neurological examination concurs, a CT examination is recommended if disc surgery is considered. Hip arthrosis can change into aseptic arthritis and cause pain. The lucencies in the transverse processes are likely incidental findings and represent cysts. However, in case a CT is run, these vertebrae should be included.



The information and recommendations provided are based on the images presented by the referring veterinarian/sonographer. No evaluation can be communicated regarding pathology that was not visible in the image/video clips provided.

Thank you for this referral. If the clinical or image interpretation does not parallel your findings or if I



PATIENT

can be of any further assistance, please contact me.

Eric Johnson

Heike Rudolf, DVM, Dr. med. vet., DipECVDI, DVR
info@sonopath.com

SPECIES

Feline

BREED

DSH

SEX

Neutered Male

AGE

14 Years

WEIGHT

4.6 kg

INTERPRETED BY

Heike Rudolf, DVM, Dr.
med. Vet., DipECVDI
DVR

**IMAGING
PERFORMED BY**

Dr. Sherry Vartanian

HOSPITAL NAME

Green Dog Dental &
Wellness

REFERRING VET

Dr. Sherry Vartanian

INVOICE

35442

DATE

11/7/25