


**PATIENT PRESENTING CLINICAL SIGNS**

Sophie McGann weak hind end.  
 Abnormal PE/Chem/CBC/UA Results: blood work unremarkable

**SPECIES RADIOGRAPHIC STUDY OF THE T- AND L SPINE**

Canine 1x VD spine C4 to L5, 1x VD spine L2 to tail

**RADIOGRAPHIC FINDINGS**

**BREED** Pug No signs of aggressive osteolysis have been identified. T12 and T13 are superimposed onto the gastric air and appear slightly heterogenous in opacity.

Pug

**SEX**

Smooth, curved bone spurs are located on the abaxial aspects of the caudal endplate of L2. An oval, bone opacity is located in the right intervertebral foramen.

Spayed Female

The disc spaces appear to have a homogeneous width.

**RADIOGRAPHIC DIAGNOSIS**

**AGE** L2/3

- Lateral spondylosis
- Mineral opacity in intervertebral foramen

**INTERPRETED BY**

Heike Rudolf, DVM,  
 Dr. med. Vet.,  
 DipECVDI DVR

**INTERPRETATION OF THE FINDINGS & FURTHER RECOMMENDATIONS**

The changes at L2/3 are suggestive of extruded, mineralized disc material. Accurate positioning of the spine is difficult, even under G.A., and cord compression can only be identified with myelography or in cross sectional imaging. Multiple areas of compression may be present. Depending on the severity of the clinical signs, CT or MRI is recommended to plan the surgical approach.

**HOSPITAL NAME**

St. Catharine's AH

**TECHNICAL COMMENTS**

I could not open image\_20211105162341

**REFERRING VET**

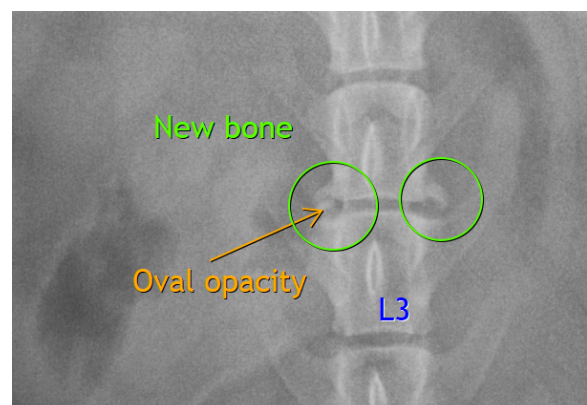
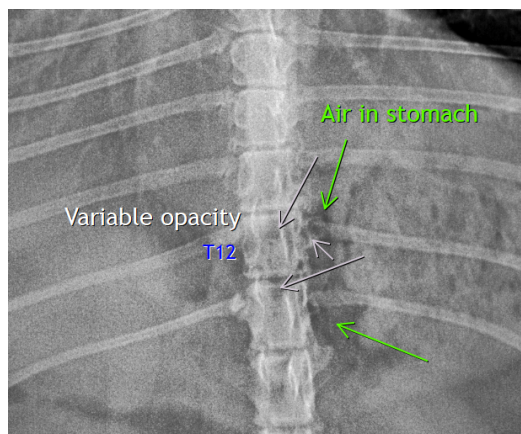
Dr. Boctor

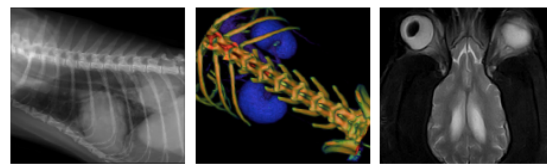
**INVOICE**

26905

**DATE**

11/5/21





**PATIENT**

Sophie McGann

**SPECIES**

Canine

**The information and recommendations provided are based on the images presented by the referring veterinarian. No evaluation can be communicated regarding pathology that was not visible in the image/video clips provided.**

**BREED**

Pug

Thank you for this referral. If the clinical or image interpretation does not parallel your findings or if I can be of any further assistance please contact me.

**Heike Rudolf**, DVM, Dr. med. vet., DipECVDI, DVR  
dr.h.rudorf@gmail.com

**SEX**

Spayed Female

**AGE**

7 Years

**INTERPRETED BY**

Heike Rudolf, DVM,  
Dr. med. Vet.,  
DipECVDI DVR

**HOSPITAL NAME**

St. Catharine's AH

**REFERRING VET**

Dr. Boctor

**INVOICE**

26905

**DATE**

11/5/21