


**PATIENT PRESENTING CLINICAL SIGNS**

Lucky Gilbert

Reason for Visit: HEARTWORMS History: P IS A 2Y6M OLD M/N YORKIE MIX PRESENTING TODAY FOR HEARTWORMS. P IS POSITIVE FOR HEARTWORMS O INTERESTED IN PURSUING TREATMENT. O BROUGHT P TO VACCINE CLINIC YESTERDAY FOUND OUT P IS HW POS. P WAS ON TRIO FOR PAST 7 MONTHS OR SO. CHECK SKIN O THINKS INSECT BITES ALL OVER BY EARS, BELLY. O NOTICED 10 DAYS AGO. NO OTHER PROBLEMS/CONCERNS. O STATES P WHEEZES HAS BEEN DOING THAT SINCE O GOT 2 YEARS AGO.

**SPECIES**

Canine

Abnormal PE/Chem/CBC/UA Results: CV/Respiratory: Normal heart rate and rhythm, no murmur, pulses strong and synchronous, normal bronchovesicular sounds. EENT: Clear OU and AU. No nasal discharge. No cough on tracheal palpation. Oral cavity: Mild dental tartar

**BREED**

Yorkie X

**RADIOGRAPHIC STUDY OF THE THORAX**

2 orthogonal views.

**SEX**

Neutered Male

**RADIOGRAPHIC FINDINGS**

The body condition score is 6/9 with smooth alternating layers of fat and soft tissue opacity.

**AGE**

2 Years 6 Months

The bony structures appear physiological.

The lungs are in contact with the thoracic boundaries and the tips are pointed. The lobar vessels are clearly visible to the tertiary branches. The bronchial tree is thin walled and tapers uniformly towards the periphery.

**INTERPRETED BY**

 Heike Rudolf, DVM,  
 Dr. med. Vet.,  
 DipECVDI DVR

The cranial mediastinum is of physiological size and opacity. The trachea dips at the carina.

The cardiac silhouette occupies 75% of the chest height and 3 intercostal spaces. No chamber or outflow tract enlargement is evident.

**HOSPITAL NAME**

DPC Vet Hospital

**RADIOGRAPHIC DIAGNOSIS**

- Physiological study

**INTERPRETATION OF THE FINDINGS & FURTHER RECOMMENDATIONS**
**REFERRING VET**

Dr. Rivera

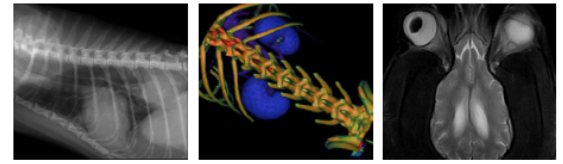
I can see no abnormalities. Echocardiography is recommended to rule out adult worms in the right atrium.

**INVOICE**

26903

**DATE**

11/5/21



**PATIENT**

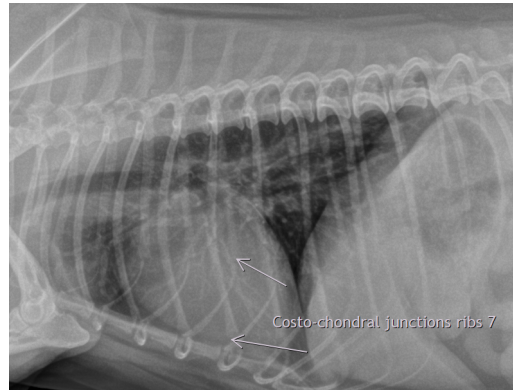
Lucky Gilbert

**SPECIES**

Canine

**BREED**

Yorkie X



**SEX**

Neutered Male

**AGE**

2 Years 6 Months

**The information and recommendations provided are based on the images presented by the referring veterinarian. No evaluation can be communicated regarding pathology that was not visible in the image/video clips provided.**

Thank you for this referral. If the clinical or image interpretation does not parallel your findings or if I can be of any further assistance please contact me.

**Heike Rudolf, DVM, Dr. med. vet., DipECVDI, DVR**  
dr.h.rudorf@gmail.com

**INTERPRETED BY**

Heike Rudolf, DVM,  
Dr. med. Vet.,  
DipECVDI DVR

**HOSPITAL NAME**

DPC Vet Hospital

**REFERRING VET**

Dr. Rivera

**INVOICE**

26903

**DATE**

11/5/21