


PATIENT PRESENTING CLINICAL SIGNS

Louie Watts reduced appetite for 3 days
 Abnormal PE/Chem/CBC/UA Results: unremarkable

SPECIES RADIOGRAPHIC STUDY OF THE ABDOMEN

Canine RLR, LLR, VD

RADIOGRAPHIC FINDINGS

BREED The body condition score is 7/9 with smooth alternating layers of fat and soft tissue opacity.

Goldendoodle The last visible thoracic vertebra has a rudimentary rib on the L and a short and thin rib on the R.

SEX The abdominal detail is good; diaphragm and abdominal wall are intact.

Neutered Male The liver is located within the costal arch and the caudo-ventral lobe is pointed.

The spleen runs parallel to the left abdominal wall and appears of physiological size and opacity.

AGE The stomach contains a mixture of food and air; in neither recumbency does the pyloric region contain air. The small intestinal loops have a physiological distribution and size. Colon and rectum are in a physiological position.

7 Years

INTERPRETED BY

Heike Rudolf, DVM,
 Dr. med. Vet.,
 DipECVDI DVR

Both renal shadows have a physiological size, shape and opacity; the surfaces appear smooth. The bladder is located well within the abdominal cavity and contains a moderate amount of homogeneous fluid opacity. The space between caudal bladder and pubis is 3cm long and is superimposed by the leg muscles.

The sublumbar region appears physiological.

HOSPITAL NAME RADIOGRAPHIC DIAGNOSIS

- St. Catharine's AH
- Transitional vertebra
 - 3 cm long gap between bladder neck and pubis
 - Fluid filled pylorus

REFERRING VET

Dr. Boctor

INTERPRETATION OF THE FINDINGS & FURTHER RECOMMENDATIONS

The structure caudal to the bladder could represent an enlarged prostate gland which would be unusual for a neutered male dog; rectal examination and abdominal ultrasound are recommended. The lack of air in the pyloric region could be a physiological variation of slow-moving gas but could also represent wall thickening or foreign material. Abdominal ultrasound is recommended to rule out a mass.

INVOICE

26902

DATE

11/5/21



PATIENT

Louie Watts

SPECIES

Canine

BREED

Goldendoodle

SEX

Neutered Male

AGE

7 Years

INTERPRETED BY

Heike Rudolf, DVM,
Dr. med. Vet.,
DipECVDI DVR

HOSPITAL NAME

St. Catharine's AH

REFERRING VET

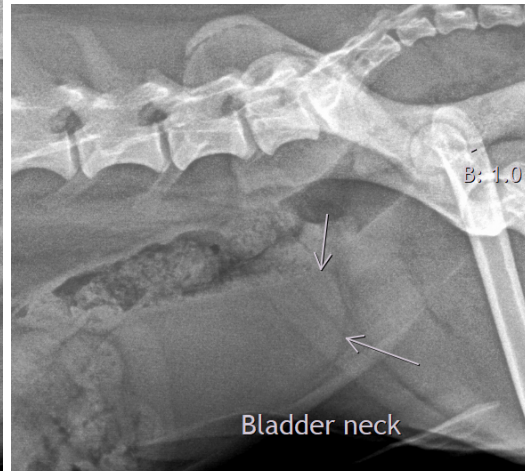
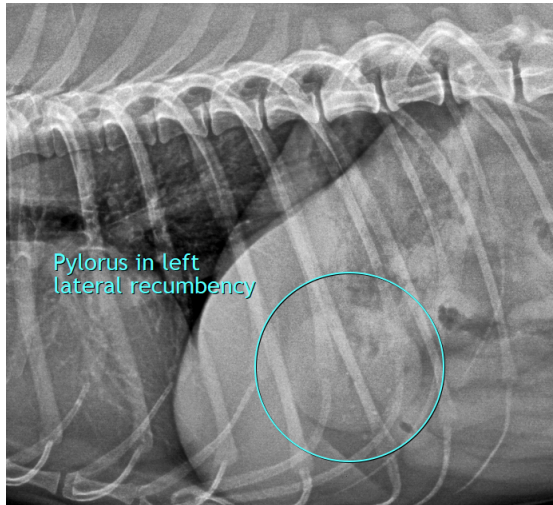
Dr. Boctor

INVOICE

26902

DATE

11/5/21



The information and recommendations provided are based on the images presented by the referring veterinarian. No evaluation can be communicated regarding pathology that was not visible in the image/video clips provided.

Thank you for this referral. If the clinical or image interpretation does not parallel your findings or if I can be of any further assistance please contact me.

Heike Rudolf, DVM, Dr. med. vet., DipECVDI, DVR
dr.h.rudorf@gmail.com