



PATIENT

Max Beaudoin

PRESENTING CLINICAL SIGNS

Rigid, hesitant to jump up or bend down low, laying down
Abnormal PE/Chem/CBC/UA Results: BW unremarkable

SPECIES

Canine

RADIOGRAPHIC STUDY OF SPINE, SHOULDERS AND PELVIS

1x r lateral thorax including C-spine and both, superimposed, fore arms, 1x VD thorax including both shoulders, 2 orthogonal views of the abdomen, VD pelvis including stifles.

BREED

Afghan Hound Mix

RADIOGRAPHIC FINDINGS

Spine

The surrounding muscles and fat layers appear physiological.

No signs of aggressive osteolysis have been identified. All skeletal structures are well mineralized and have smooth surfaces. The dorsal spinous processes (DSP) of C6 and C7 converge and appear to be fused.

SEX

Male Neuter

The thoracic and lumbar facet joints appear to be congruent.

LS disc space and intervertebral foramen (IVF) appear reduced. All cervical disc spaces appear narrow.

AGE

10 Years

Shoulders

The bones are well mineralized, have a normal trabecular structure and smooth, continuous surfaces. Cortical-medullary development and differentiation of the long bones are physiological.

The shoulder joints appear congruent with even subchondral bone surfaces. Swelling around the joints is not apparent.

INTERPRETED BY

Heike Rudorf, DVM,
Dr. med. Vet.,
DipECVDDI DVR

HOSPITAL NAME

St. Catherine's Animal
Hospital

Pelvis

The center of both femoral heads is superimposed onto the dorsal acetabular edge, taking into account the L sided tilt. Both lateral joint spaces are slightly wide. No new bone formation is evident.

REFERRING VET

Dr. Masoud

RADIOGRAPHIC DIAGNOSIS

- Possible cauda equina
- Congenital vertebral anomaly C6/7
- Mild, bilateral HD

INVOICE

48584

INTERPRETATION OF THE FINDINGS & FURTHER RECOMMENDATIONS

Accurate positioning of the spine is difficult even under G.A. and cord compression can only be identified with myelography or in cross sectional imaging. CT or MRI is recommended in case an extruded disc needs to be removed.

DATE

11-26-21

TECHNICAL COMMENTS

Rotation C-spine.



PATIENT

Max Beaudoin

SPECIES

Canine

BREED

Afghan Hound Mix

SEX

Male Neuter

AGE

10 Years

INTERPRETED BY

Heike Rudorf, DVM,
Dr. med. Vet.,
DipECVDI DVR

HOSPITAL NAME

St. Catherine's Animal
Hospital

REFERRING VET

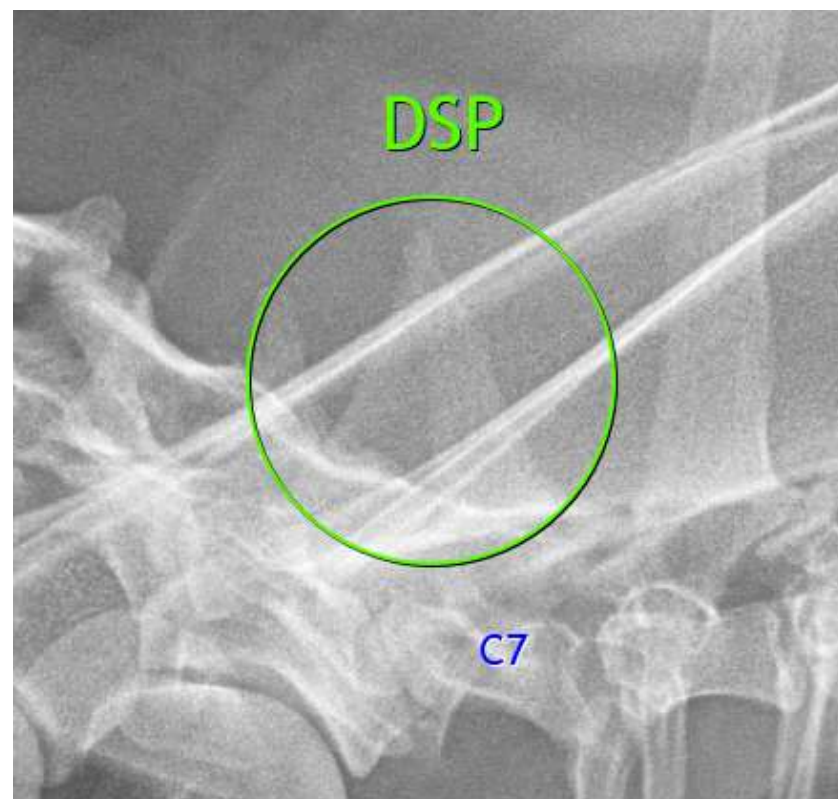
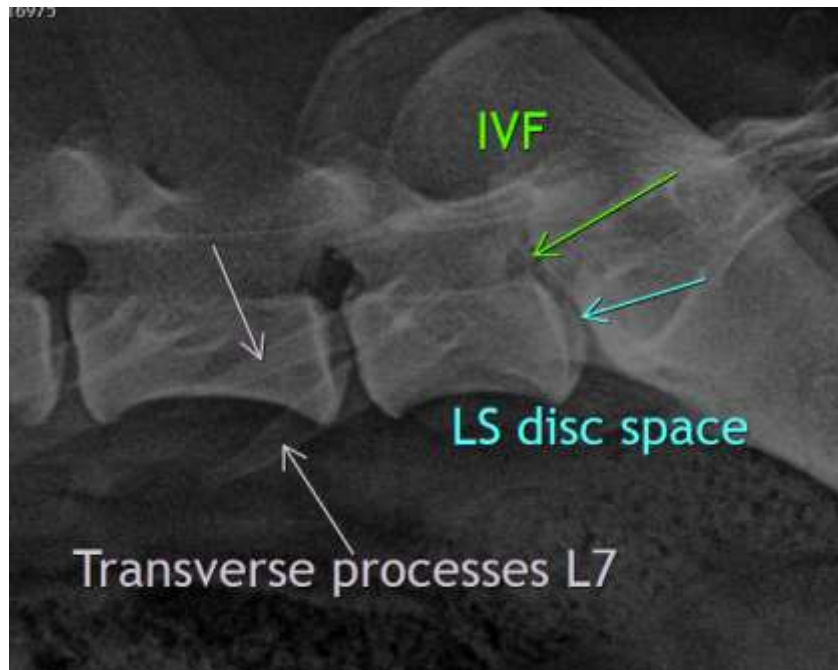
Dr. Masoud

INVOICE

48584

DATE

11-26-21





PATIENT

Max Beaudoin

The information and recommendations provided are based on the images presented by the referring veterinarian. No evaluation can be communicated regarding pathology that was not visible in the image/video clips provided.

SPECIES

Canine

Thank you for this referral. If the clinical or image interpretation does not parallel your findings or if I can be of any further assistance please contact me.

BREED

Afghan Hound Mix

Heike Rudolf, DVM, Dr. med. vet., DipECVDI, DVR
Dr.H.Rudorf@gmail.com

SEX

Male Neuter

AGE

10 Years

INTERPRETED BY

Heike Rudolf, DVM,
Dr. med. Vet.,
DipECVDI DVR

HOSPITAL NAME

St. Catherine's Animal
Hospital

REFERRING VET

Dr. Masoud

INVOICE

48584

DATE

11-26-21