

**PATIENT**

Dude Loughran

SPECIES

Canine

BREED

English Bulldog

SEX

Male Neutered

AGE

7 Years

INTERPRETED BYHeike Rudolf, DVM,
Dr. med. Vet.,
DipECVDDI DVR**HOSPITAL NAME**POCONO PEAK
VETERINARY
CENTER..**REFERRING VET**

Dr. Katie Laury

INVOICE

48585

DATE

11-26-21

PRESENTING CLINICAL SIGNS

11/24/21: Presented for ER visit-PT yelped from other room, O checked on him, neck was stiff in appearance, unable to look up. O. says within in hour, PT was screaming and crying in pain, appeared panicked, then lethargic. Urinated in exam room as soon as he got in, very unlike PT's normal behavior. Hx of Lyme + in 2018, was treated, per C6 results 11/26/21- pt not actively infected w/ lyme. Current Meds: Neopolydex eyedrops, Apoquel, Cephalexin, Hexaderm shampoo Diet unchanged E/D/U/D WNL no V/D/C/S
Abnormal PE/Chem/CBC/UA Results: Hanging head low, painful on range of motion of neck, stiff and slow when walking.

RADIOGRAPHIC STUDY OF THE C-SPINE

2 orthogonal views C2- T13

RADIOGRAPHIC FINDINGS

No signs of aggressive osteolysis have been identified. The odontoid peg is not highlighted.

The surrounding muscles and fat layers appear physiological.

T8 and 12 are wedge shaped. The skeletal structures are well mineralized and have smooth surfaces.

RADIOGRAPHIC DIAGNOSIS

- Congenital vertebral anomalies

INTERPRETATION OF THE FINDINGS & FURTHER RECOMMENDATIONS

Without a history of trauma, odontoid peg abnormalities are unlikely, considering the age of the dog. Disc disease is very likely. Accurate positioning of the spine is difficult even under G.A. and cord compression can only be identified with myelography or in cross sectional imaging. Considering the severity of the clinical signs, CT or MRI is recommended in case an extruded disc needs to be removed.



PATIENT

Dude Loughran

SPECIES

Canine

BREED

English Bulldog

SEX

Male Neutered

AGE

7 Years

INTERPRETED BY

Heike Rudolf, DVM,
Dr. med. Vet.,
DipECVDDI DVR

HOSPITAL NAME

POCONO PEAK
VETERINARY
CENTER..

REFERRING VET

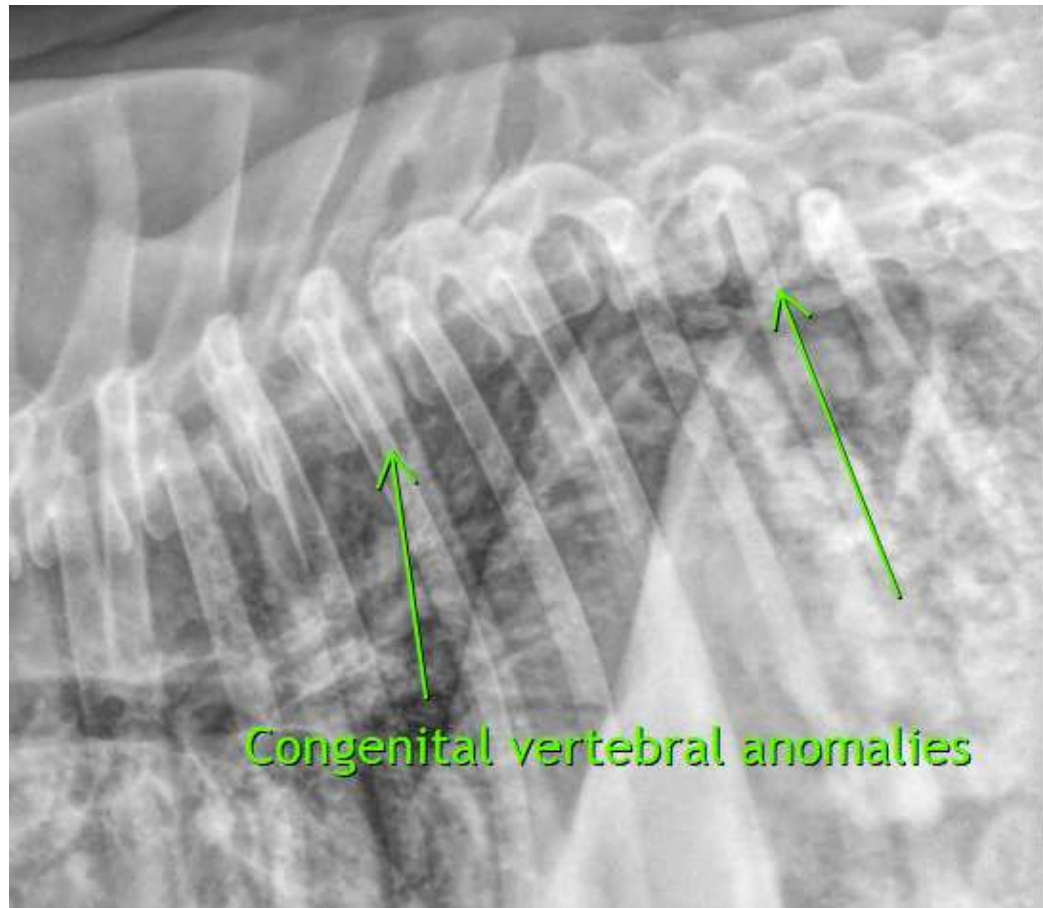
Dr. Katie Laury

INVOICE

48585

DATE

11-26-21



The information and recommendations provided are based on the images presented by the referring veterinarian. No evaluation can be communicated regarding pathology that was not visible in the image/video clips provided.

Thank you for this referral. If the clinical or image interpretation does not parallel your findings or if I can be of any further assistance please contact me.

Heike Rudolf, DVM, Dr. med. vet., DipECVDDI, DVR
Dr.H.Rudorf@gmail.com