



**PATIENT PRESENTING CLINICAL SIGNS**

**Tyson Plumley** History: Coughing especially after getting up in the morning Getting tired on walks Hx of seizures, well controlled on Phenobarbital

**SPECIES RADIOGRAPHIC STUDY OF THE THORAX**

**Canine** The body condition score is 8/9 with smooth alternating layers of fat and soft tissue opacity. Mild spondylosis is present L1/2.

**BREED** The lungs are in contact with the thoracic boundaries and the tips are pointed. The lobar vessels are visible. The bronchial tree is thin walled and tapers uniformly towards the periphery. The degree of pulmonary expansion is fair at best.

**Shih Tzu**

**SEX** The cranial mediastinum is of physiological size and opacity. The trachea runs parallel to the thoracic vertebrae and is in line with the carina.

**Neutered Male** The cardiac silhouette occupies 80% of the chest height and 3.5 intercostal spaces (VHS 10.5). No chamber or outflow tract enlargement is evident. A large amount of pericardial fat surrounds the heart on the DV view.

**AGE** The liver lobes are rounded and extend beyond the costal arch. The gastric axis is caudally rotated.

**12 Years RADIOGRAPHIC DIAGNOSIS**

- Hepatomegaly

**INTERPRETED BY INTERPRETATION OF THE FINDINGS & FURTHER RECOMMENDATIONS**

**Heike Rudolf, DVM, Dr. med. Vet., DipECVDI DVR** Cardiac size is still within the physiological range for a small dog but should a murmur be present, echocardiography is recommended. Hepatomegaly can be the result of fatty infiltrate which is commonly seen with diabase mellitus and Cushing's disease. The latter can cause muscle weakness and should be ruled out with biochemistry and ultrasound of the adrenals. Changes in architecture and echogenicity of the liver may necessitate sampling. Tracheal o bronchial collapse can explain the cough and trachea-bronchoscopy is necessary to rule them out.

**HOSPITAL NAME**

**Balmy Beach PH** Obesity is known to worsen clinical signs of cough and impair lung function; weight control is strongly recommended.

**REFERRING VET**

**Dr. Singh**

**INVOICE**

18222

**DATE**

11/25/22



**PATIENT**

Tyson Plumley

**SPECIES**

Canine

**BREED**

Shih Tzu

**SEX**

Neutered Male

**AGE**

12 Years

**INTERPRETED BY**

Heike Rudorf, DVM,  
Dr. med. Vet.,  
DipECVDI DVR

**HOSPITAL NAME**

Balmy Beach PH

**REFERRING VET**

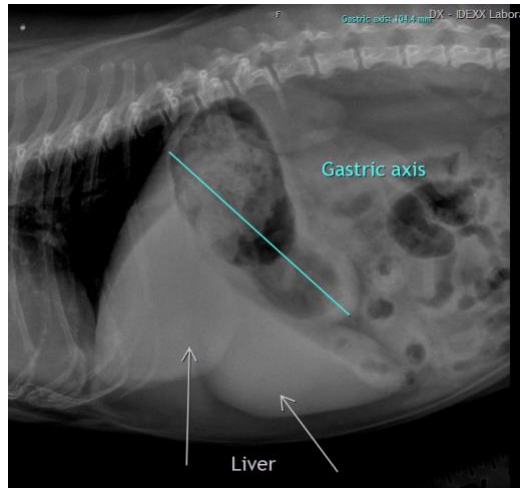
Dr. Singh

**INVOICE**

18222

**DATE**

11/25/22



**The information and recommendations provided are based on the images presented by the referring veterinarian/sonographer. No evaluation can be communicated regarding pathology that was not visible in the image/video clips provided.**

Thank you for this referral. If the clinical or image interpretation does not parallel your findings or if I can be of any further assistance please contact me.

**Heike Rudorf**, DVM, Dr. med. vet., DipECVDI, DVR  
dr.h.rudorf@gmail.com