



PATIENT PRESENTING CLINICAL SIGNS

PATIENT Autumn Filan **PRESENTING CLINICAL SIGNS** History: Acute onset of NWB/limping on LF leg that started yesterday. Sore to touching of left shoulder area.

SPECIES Abnormal PE/Chem/CBC/UA Results: Favoring LF, blood diagnostics NSF.

SPECIES Canine

RADIOGRAPHIC STUDY OF THE LEFT SHOULDER

The trabecular structure in the caudal humeral head and neck is lost and replaced by lysis. The caudal humeral neck is thickened with caudal displacement of a thin cortex. The medullary cavity of the humeral diaphysis shows a patchy, increase in opacity.

BREED

BREED Greyhound

RADIOGRAPHIC DIAGNOSIS

- Space occupying, destructive lesion

SEX

INTERPRETATION OF THE FINDINGS & FURTHER RECOMMENDATIONS

SEX Spayed Female

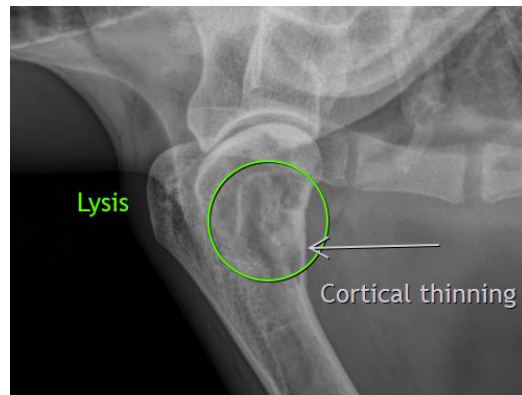
The changes are consistent with a tumor, most likely an osteosarcoma. Extension along the medullary cavity is possible but this should be compared to the other leg. A sample should be obtained to verify the diagnosis and identify the type of tumor. Thoracic imaging is necessary if treatment is considered.

AGE

AGE 12 Years 10 Months

INTERPRETED BY

INTERPRETED BY Heike Rudolf, DVM, Dr. med. Vet., DipECVDI DVR



HOSPITAL NAME

HOSPITAL NAME Pocono Peak VC

The information and recommendations provided are based on the images presented by the referring veterinarian/sonographer. No evaluation can be communicated regarding pathology that was not visible in the image/video clips provided.

REFERRING VET

REFERRING VET Dr. Nicole Norris-Carney

Thank you for this referral. If the clinical or image interpretation does not parallel your findings or if I can be of any further assistance please contact me.

INVOICE

INVOICE Heike Rudolf, DVM, Dr. med. vet., DipECVDI, DVR
dr.h.rudorf@gmail.com

18214

DATE

11/25/22



PATIENT

Autumn Filan

SPECIES

Canine

BREED

Greyhound

SEX

Spayed Female

AGE

12 Years 10 Months

INTERPRETED BY

Heike Rudolf, DVM,
Dr. med. Vet.,
DipECVDI DVR

HOSPITAL NAME

Pocono Peak VC

REFERRING VET

Dr. Nicole Norris-
Carney

INVOICE

18214

DATE

11/25/22