


PATIENT PRESENTING CLINICAL SIGNS

Ozzy Jensen dog got a skin laceration on chest at day care today , not extending deep to SQ , no breathing issue, took chest rads to make sure chest look ok
 Abnormal PE/Chem/CBC/UA Results: Creatinine slight high 112 (normal up to 106 unit)

SPECIES RADIOGRAPHIC STUDY OF THE THORAX

Canine
 RLR, LLR, VD

BREED RADIOGRAPHIC FINDINGS

Lab X
 The body condition score is 6/9 with smooth alternating layers of fat and soft tissue opacity.
 The bony structures appear physiological.

SEX
 Neutered Male
 The lungs are in contact with the thoracic boundaries and they are well aerated. Their edges are rounded on the lateral views. The lobar vessels are clearly visible to the tertiary branches. The bronchial tree is thin walled and tapers uniformly towards the periphery.

AGE
 22 Months
 The cranial mediastinum is of physiological size and opacity. The trachea diverges from the thoracic vertebrae and the carina is located at T5.

The cardiac silhouette occupies 75% of the chest height and 3 intercostal spaces. No chamber or outflow tract enlargement is evident.

INTERPRETED BY RADIOGRAPHIC DIAGNOSIS

Heike Rudolf, DVM,
 Dr. med. Vet.,
 DipECVDI DVR

- No pneumothorax is present

INTERPRETATION OF THE FINDINGS & FURTHER RECOMMENDATIONS

HOSPITAL NAME
 Edmonton West AH
 I can see no changes that should cause concern. The answers, I hope, to your questions are given in association with the pictures below.

TECHNICAL COMMENTS

REFERRING VET
 Dr. Sumeet Sharma
 What is that scalloping which look like air bronchogram on all view? I am concerned about black curvy shadowing on all views. I don't know what you refer to. But I assume it is the scalloped ventral lung lobes of one side which are highlighted due to the mild rotation.

INVOICE

33098

DATE

11/25/21



PATIENT

Ozzy Jensen

SPECIES

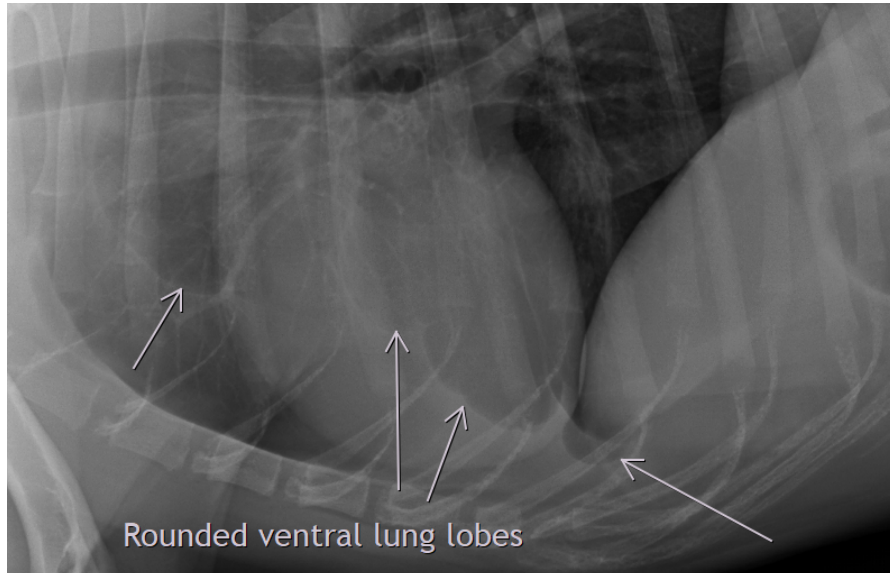
Canine

BREED

Lab X

SEX

Neutered Male



AGE

22 Months

INTERPRETED BY

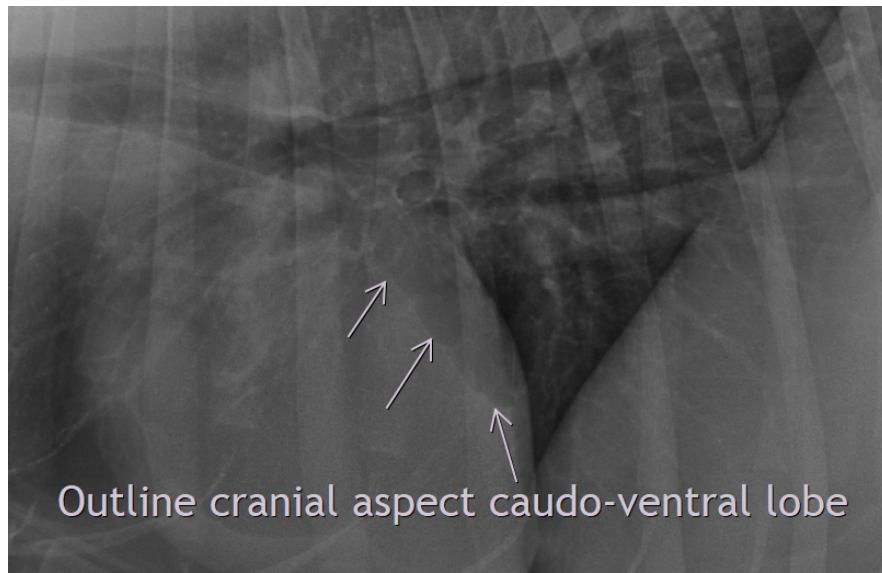
Heike Rudorf, DVM,
Dr. med. Vet.,
DipECVDI DVR

HOSPITAL NAME

Edmonton West AH

REFERRING VET

Dr. Sumeet Sharma



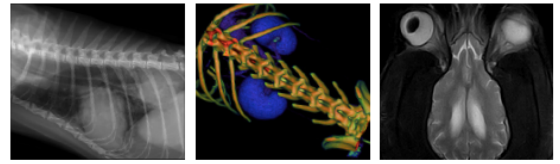
What is that sharp line, vertical on left caudal lung lobe on vd view? The mediastinum that separates accessory from left caudal lobe.

INVOICE

33098

DATE

11/25/21



PATIENT

Ozzy Jensen

SPECIES

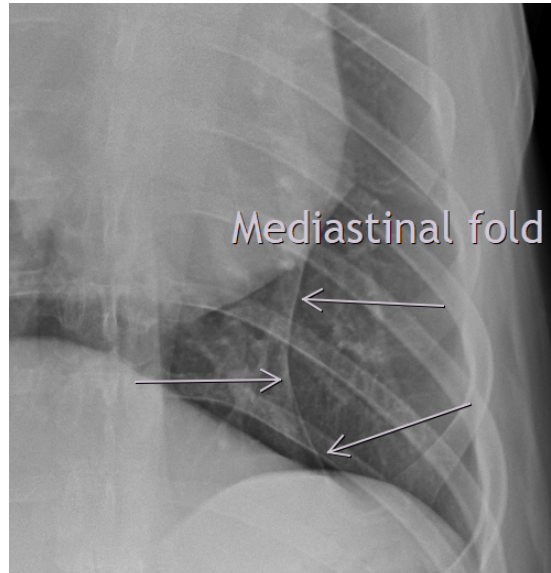
Canine

BREED

Lab X

SEX

Neutered Male



AGE

22 Months

The information and recommendations provided are based on the images presented by the referring veterinarian. No evaluation can be communicated regarding pathology that was not visible in the image/video clips provided.

INTERPRETED BY

Heike Rudolf, DVM,
Dr. med. Vet.,
DipECVDI DVR

Thank you for this referral. If the clinical or image interpretation does not parallel your findings or if I can be of any further assistance please contact me.

Heike Rudolf, DVM, Dr. med. vet., DipECVDI, DVR
dr.h.rudorf@gmail.com

HOSPITAL NAME

Edmonton West AH

REFERRING VET

Dr. Sumeet Sharma

INVOICE

33098

DATE

11/25/21