


PATIENT PRESENTING CLINICAL SIGNS

Elmo Howe Patient presented for vomiting 4 times today as well as having diarrhea. Not wanting to eat which is unusual for pet. Pet has Cushings disease
 Abnormal PE/Chem/CBC/UA Results: Leukocytosis with neutrophilia, ALP 2003, globulins low end normal 2.3

SPECIES

Canine

RADIOGRAPHIC STUDY OF THE ABDOMEN

RLR, LLR, VD

BREED

Bichon Frise

RADIOGRAPHIC FINDINGS

The body condition score is 5/9.

SEX

Neutered Male

Arthrosis is present in the right stifle joint and metal implants are present in the tibia.

The abdominal detail is in line with the BCS; diaphragm and abdominal wall are intact.

The ventral liver lobe extends beyond the costal arch and is rounded.

AGE

14 Years

The spleen appears physiological.

The stomach contains a moderate amount of air and its body and the pylorus appear to be cranially displaced in the region of the transverse colon. The small intestinal loops appear physiological. The transverse colon is straight and the walls are thick (approx. 0.3cm) for approx. 7cm. The mucosal surface in the region of the thickening is undulating.

INTERPRETED BY

 Heike Rudolf, DVM,
 Dr. med. Vet.,
 DipECVDI DVR

The left renal shadow has a physiological size, shape and opacity; the right is obscured by intestinal structures. The bladder is located in the abdominal cavity and contains a small amount of fluid and small calculi in the center.

HOSPITAL NAME

Boca Park AH

The prostatic shadow is just visible cranial to the pubic brim.

The sublumbar region appears physiological.

REFERRING VET

Dr. Corrina Gorgon

RADIOGRAPHIC DIAGNOSIS

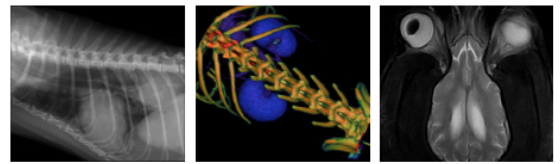
- Transverse colon
 - Wall thickening
 - Mucosal irregularity
- Hepatomegaly
- Prostatomegaly
- Cystic calculi
- Stifle arthrosis and implants

INVOICE

33090

DATE

11/24/21



PATIENT INTERPRETATION OF THE FINDINGS & FURTHER RECOMMENDATIONS

Elmo Howe

Colonic wall thickening can be the result of tumor infiltrate or ulcerative colitis. The straight appearance of the transverse colon suggests rigidity. A visible prostatic shadow in a neutered male dog is suspicious for a tumor but depends on the time of castration. Abdominal ultrasound is recommended to evaluate especially colon, prostate, urinary tract and liver. Obtaining samples of abnormal regions (possibly also lymph nodes) is necessary and grab biopsies during colonoscopy may be the best option.

SPECIES

Canine

BREED

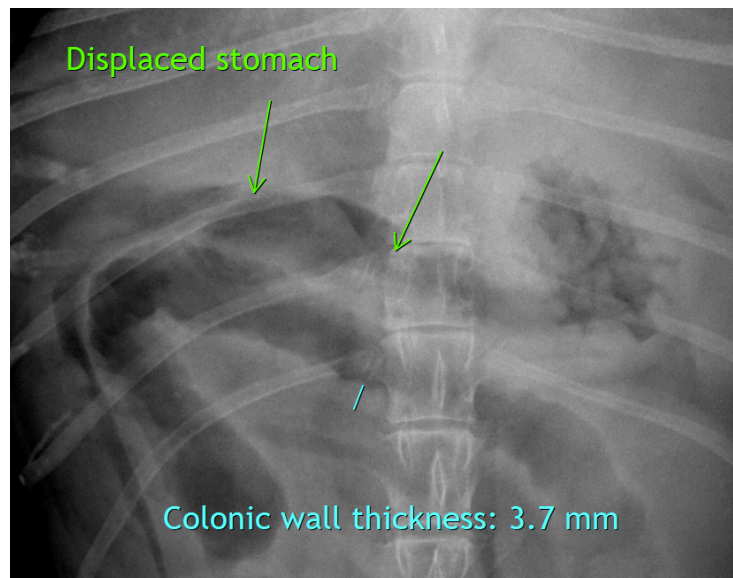
Bichon Frise

SEX

Neutered Male

AGE

14 Years



INTERPRETED BY

Heike Rudolf, DVM,
Dr. med. Vet.,
DipECVDI DVR

HOSPITAL NAME

Boca Park AH

REFERRING VET

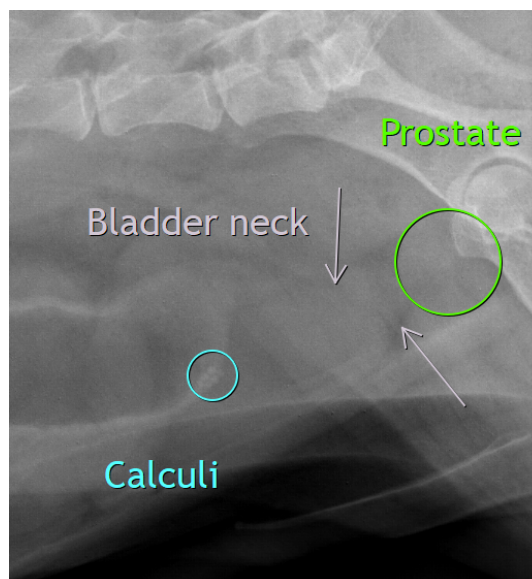
Dr. Corrina Gorgon

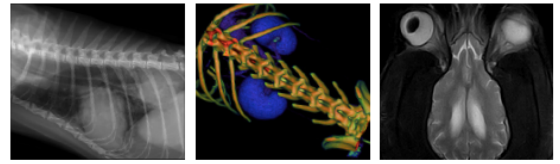
INVOICE

33090

DATE

11/24/21





PATIENT

Elmo Howe

The information and recommendations provided are based on the images presented by the referring veterinarian. No evaluation can be communicated regarding pathology that was not visible in the image/video clips provided.

SPECIES

Canine

Thank you for this referral. If the clinical or image interpretation does not parallel your findings or if I can be of any further assistance please contact me.

BREED

Bichon Frise

Heike Rudolf, DVM, Dr. med. vet., DipECVDI, DVR
dr.h.rudorf@gmail.com

SEX

Neutered Male

AGE

14 Years

INTERPRETED BY

Heike Rudolf, DVM,
Dr. med. Vet.,
DipECVDI DVR

HOSPITAL NAME

Boca Park AH

REFERRING VET

Dr. Corrina Gorgon

INVOICE

33090

DATE

11/24/21