



PATIENT PRESENTING CLINICAL SIGNS

PATIENT Mollie Utreras
PRESENTING CLINICAL SIGNS History: Mollie had a syncope yesterday, urinated , and almost fainted, after she recovered had another episode in the elevator, she has a heart murmur , and her tummy seems extended .today B.A.R .

SPECIES RADIOGRAPHIC STUDY OF THE THORAX

SPECIES Canine
 The body condition score is 6/9 with smooth alternating layers of fat and soft tissue opacity.
 The bony structures appear physiological.

BREED

BREED Schnauzer
 The lungs are in contact with the thoracic boundaries and the tips are pointed. The lobar vessels are obscured, especially in the hilar region and the caudo-dorsal lobes. The bronchial tree is enhanced in these areas.

SEX

SEX Spayed Female
 The cranial mediastinum is of physiological size and opacity. The trachea runs parallel to the thoracic vertebrae and the carina is in line with the trachea. The lateral deviation of the left main stem bronchus is pronounced (splitting of main stem bronchi).

AGE

AGE 9 Years 9 Months
 The cardiac silhouette occupies 90% of the chest height and 3.5 intercostal spaces (VHS 13). The caudal heart border is straight and tenting of the left atrium is present.
 The ventral liver lobe is slightly blunted, and the tip extends just beyond the costal arch. A urinary calculus is present in an empty bladder.

RADIOGRAPHIC DIAGNOSIS

INTERPRETED BY

INTERPRETED BY Heike Rudolf, DVM,
 Dr. med. Vet.,
 DipECVDI DVR
 • L sided cardiomegaly
 • Interstitial infiltrate, moderate
 • Early hepatomegaly
 Incidental finding

HOSPITAL NAME

HOSPITAL NAME DPC Veterinary Hospital
 • Urinary calculus

INTERPRETATION OF THE FINDINGS & FURTHER RECOMMENDATIONS

Left sided cardiomegaly in an adult, large breed dog is usually due to DCM and echocardiography is recommended to assess chamber size and fractional shortening. The interstitial infiltrate most likely represents pulmonary edema due to left sided failure and the blunted liver suggests congestion due to early right sided failure.

REFERRING VET

REFERRING VET Dr. Rivera

INVOICE

INVOICE 18213

DATE

DATE 11/23/22



PATIENT

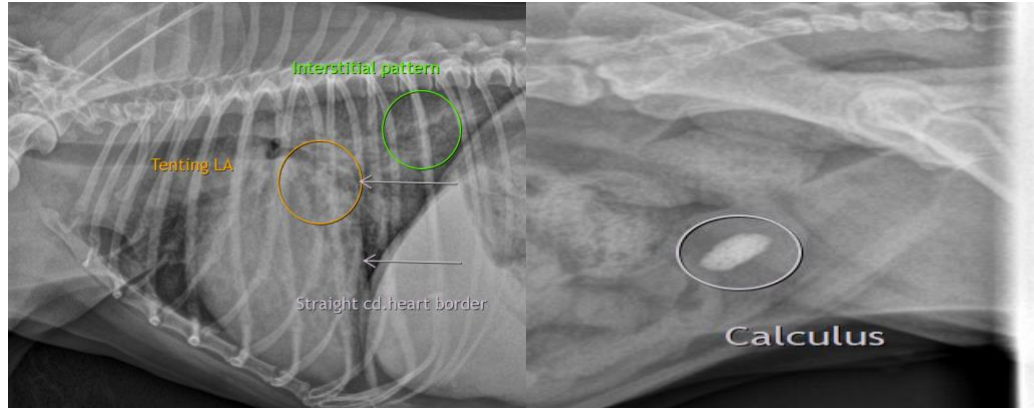
Mollie Utreras

SPECIES

Canine

BREED

Schnauzer



The information and recommendations provided are based on the images presented by the referring veterinarian/sonographer. No evaluation can be communicated regarding pathology that was not visible in the image/video clips provided.

SEX

Spayed Female

Thank you for this referral. If the clinical or image interpretation does not parallel your findings or if I can be of any further assistance please contact me.

AGE

9 Years 9 Months

Heike Rudolf, DVM, Dr. med. vet., DipECVDI, DVR
dr.h.rudorf@gmail.com

INTERPRETED BY

Heike Rudolf, DVM,
Dr. med. Vet.,
DipECVDI DVR

HOSPITAL NAME

DPC Veterinary
Hospital

REFERRING VET

Dr. Rivera

INVOICE

18213

DATE

11/23/22