

## PATIENT

Amelia Reed

## SPECIES

Canine

## BREED

Poodle Mixed

## SEX

Spayed Female

## AGE

4 Years

## WEIGHT

31

## INTERPRETED BY

Heike Rudolf, DVM, Dr.  
med. Vet., DipECVDF  
DVR

## IMAGING PERFORMED BY

Dr. Russ Lapierre

## HOSPITAL NAME

Blandford AH

## REFERRING VET

Dr. Russ Lapierre

## INVOICE

35589

## DATE

11/20/25

## PRESENTING CLINICAL SIGNS

History: 14 months prior treated for RF lameness thought to be from malassezia moist dermatitis btwn paw pads. Transient improvement when treated for dermatitis. G1 lame at walk, just perceptible head bob RF, when standing does not keep RF on the ground. No sensitivities to flexions extensions palpations nor any soft tissue swellings at that time. Chiropractic adjustments were not effective. Client has continued to monitor, no improvement in clinical signs to this time point.

Abnormal PE/Chem/CBC/UA Results: G1 lame RF, no sensitivities to palpations flexions extensions, other than moves paw away when moving hand to palpate outside lateral aspect of RF paw. will weight shift off RF when sitting.

## RADIOGRAPHIC STUDY OF FORE PAWS

The soft tissue outline on the lateral aspects of digit 5 and the medial aspect of digit 2 is bilaterally thickened with undulating surfaces.

The bones are well mineralized, have a normal trabecular structure and smooth, continuous surfaces. Cortical-medullary development and differentiation of the long bones are physiological.

Paws: all sesamoid bones are physiologically developed; their outline is smooth. On the lateral view the P2/3 joint of either digit 3 or 4 appears uneven with a cranial narrowing.

## RADIOGRAPHIC DIAGNOSIS

Bilateral

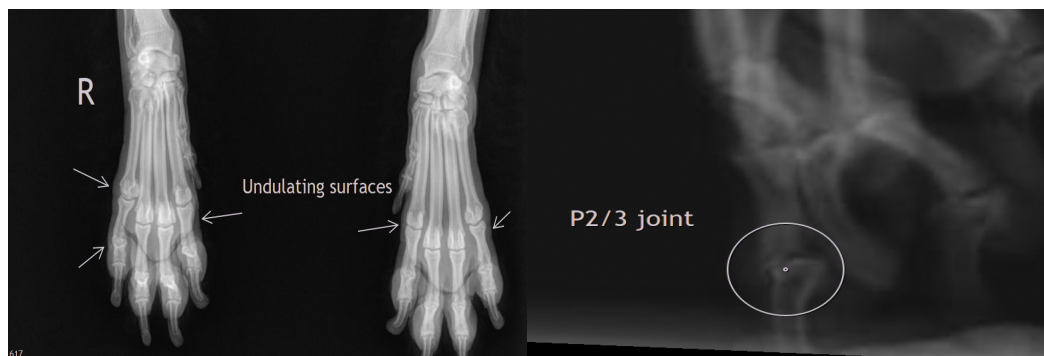
- Thickened skin digits 2 and 5
- Possible P2/3 articular changes digit 3 or 4

## INTERPRETATION OF THE FINDINGS & FURTHER RECOMMENDATIONS

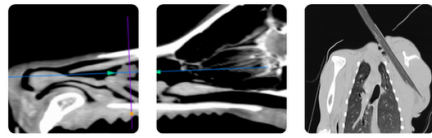
Thickened and irregular skin is compatible with the chronic skin disease described in the history. The joint incongruity of one of the longer digits is likely due to a combination of positioning and superimpositioning of structures. Manual manipulation of this joint should be repeated on both longer digits. Should this not identify a site of pain, cross sectional imaging is recommended in case a foreign body or tendinitis are the reason for the long-standing lameness. I suggest examining both entire legs so that myositis or subtle joint capsule inflammation is not missed.

## TECHNICAL COMMENTS

Tip of human phalanx on one DP image



The information and recommendations provided are based on the images presented by the



## PATIENT

Amelia Reed

## SPECIES

Canine

## BREED

Poodle Mixed

## SEX

Spayed Female

## AGE

4 Years

## WEIGHT

31

## INTERPRETED BY

Heike Rudorf, DVM, Dr.  
med. Vet., DipECVDI  
DVR

## IMAGING PERFORMED BY

Dr. Russ Lapierre

## HOSPITAL NAME

Blandford AH

## REFERRING VET

Dr. Russ Lapierre

## INVOICE

35589

## DATE

11/20/25

**referring veterinarian/sonographer. No evaluation can be communicated regarding pathology that was not visible in the image/video clips provided.**

Thank you for this referral. If the clinical or image interpretation does not parallel your findings or if I can be of any further assistance, please contact me.

**Heike Rudorf**, DVM, Dr. med. vet., DipECVDI, DVR  
[info@sonopath.com](mailto:info@sonopath.com)