



PATIENT PRESENTING CLINICAL SIGNS

Shepherd Book
MacDonald

History: Met check

RADIOGRAPHIC STUDY OF THE THORAX

SPECIES

The body condition score is 8/9 with a large amount of lateral subcutaneous fat.
Variable degrees of ventral spondylosis are present on the thoracic vertebrae.

Feline

A roundish (2.3 x 2cm) soft tissue mass is located in the left caudal lung lobe, superimposed onto the caudal vena cava. It contains a small, peripherally located gas lucency. The edges are undulating.

BREED

DSH

The cranial mediastinum is of physiological size and opacity. The trachea diverges from the thoracic vertebrae and the carina is located level with ribs 5.

SEX

Neutered Male

The cardiac silhouette occupies 75% of the chest height and 2 intercostal spaces. No chamber or outflow tract enlargement is evident.

RADIOGRAPHIC DIAGNOSIS

- Cavitating mass L caudal lobe
- Spondylosis (incidental finding)

AGE

13

INTERPRETATION OF THE FINDINGS & FURTHER RECOMMENDATIONS

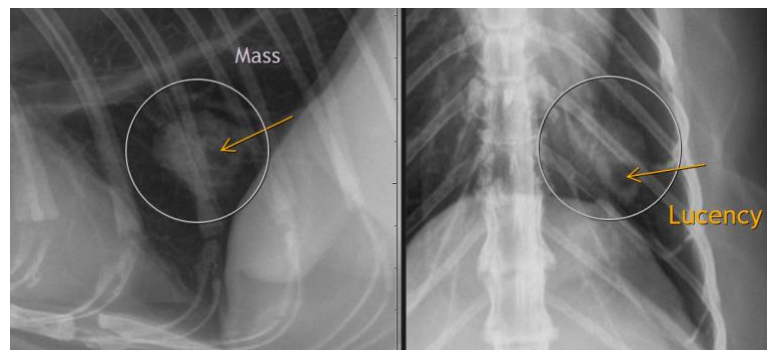
The mass could represent a primary lung tumor or an abscess, though abscess is less likely due to its ventral location. Metastasis is a differential diagnosis, though the outline is rather too irregular. Ultrasound is recommended to obtain an FNA.

INTERPRETED BY

Heike Rudolf, DVM,
Dr. med. Vet.,
DipECVDI DVR

HOSPITAL NAME

DTLA vets



REFERRING VET

Dr. Castaneda

The information and recommendations provided are based on the images presented by the referring veterinarian/sonographer. No evaluation can be communicated regarding pathology that was not visible in the image/video clips provided.

INVOICE

18133

Thank you for this referral. If the clinical or image interpretation does not parallel your findings or if I can be of any further assistance please contact me.

Heike Rudolf, DVM, Dr. med. vet., DipECVDI, DVR

DATE

11/17/22



PATIENT dr.h.rudorf@gmail.com

Shepherd Book
MacDonald

SPECIES

Feline

BREED

DSH

SEX

Neutered Male

AGE

13

INTERPRETED BY

Heike Rudorf, DVM,
Dr. med. Vet.,
DipECVDI DVR

HOSPITAL NAME

DTLA vets

REFERRING VET

Dr. Castaneda

INVOICE

18133

DATE

11/17/22