



## PATIENT

Naranjo Sweeney

## SPECIES

Feline

## BREED

DMH

## SEX

Neutered Male

## AGE

10.5 Years

## WEIGHT

12.74 Pounds

## INTERPRETED BY

Heike Rudorf, DVM, Dr.  
med. Vet., DipECVDF  
DVR

## IMAGING PERFORMED BY

Northshore Vet Techs

## HOSPITAL NAME

Northshore VH

## REFERRING VET

Dr. Ryan Knoles

## INVOICE

35537

## DATE

11/14/25

## PRESENTING CLINICAL SIGNS

History: Indoor outdoor cat. Seen two weeks ago for coughing. Radiographs taken at that time revealed bronchiolar pattern and suspected soft tissue opacity in caudal right lung field (most evident on lateral rads). Artifact was a differential at the time, so patient was treated for asthma and recheck performed today. Pet's cough has resolved and radiographs repeated today

Abnormal PE/Chem/CBC/UA Results: No abnormalities found on physical exam.

## RADIOGRAPHIC STUDY OF THE THORAX

The body condition score is 8/9 with smooth, alternating layers of fat and soft tissue opacity.

A single rib appears to be present on the left side of L1.

The cranial mediastinum is of physiologic size and opacity. The trachea diverges from the thoracic vertebrae, and the carina is located level with T5.

The degree of pulmonary expansion is good, and the lung lobes extend to the thoracic boundaries. Pulmonary vessels are visible to the secondary branches, and a mild honeycomb pattern obscures the tertiary branches on the lateral view. A tubular patch of soft tissue opacity is located along a secondary bronchus of the right caudal lobe on the VD view (approx. 2cm long, 1cm wide) and partially superimposed onto the caudal vena cava on the latera view (1.4cm long, 1cm high).

The cardiac silhouette occupies 65% of the chest height and 2 intercostal spaces. Chamber or outflow tract enlargement is not obvious, but the cranial cardiac silhouette is poorly delineated.

## RADIOGRAPHIC DIAGNOSIS

- Localized increase in opacity R caudal lobe
- Interstitial pattern

Incidental finding

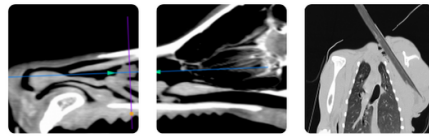
- Transitional vertebra
- Obesity

## INTERPRETATION OF THE FINDINGS & FURTHER RECOMMENDATIONS

The localized infiltrate could be due to:

- Granuloma, e.g. eosinophilic
- Localized bleeding
- infection/abscess formation
- Tumor

An interstitial lung pattern is a non-specific finding but could represent remaining changes from the treated disease. The localized infiltrate can be monitored radiographically, but should further respiratory problems occur, obtaining sampling would be the best way forward. The poor visibility of the cranial cardiac silhouette could be due to a partially collapsed lung lobe as there is no evidence of it on the DV view.



## PATIENT

Naranjo Sweeney

## SPECIES

Feline

## BREED

DMH

## SEX

Neutered Male

## AGE

10.5 Years

## WEIGHT

12.74 Pounds

## INTERPRETED BY

Heike Rudorf, DVM, Dr.  
med. Vet., DipECVDI  
DVR

## IMAGING PERFORMED BY

Northshore Vet Techs

## HOSPITAL NAME

Northshore VH

## REFERRING VET

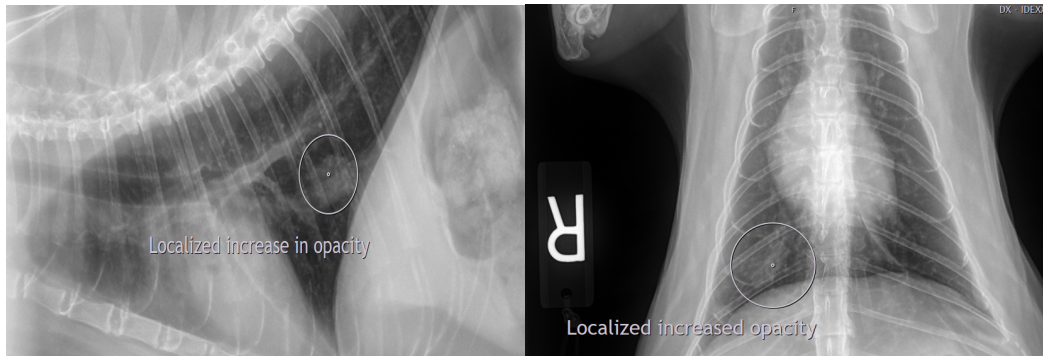
Dr. Ryan Knoles

## INVOICE

35537

## DATE

11/14/25



**The information and recommendations provided are based on the images presented by the referring veterinarian/sonographer. No evaluation can be communicated regarding pathology that was not visible in the image/video clips provided.**

Thank you for this referral. If the clinical or image interpretation does not parallel your findings or if I can be of any further assistance, please contact me.

**Heike Rudorf, DVM, Dr. med. vet., DipECVDI, DVR**  
[info@sonopath.com](mailto:info@sonopath.com)