



## PATIENT

Kobi Skeen

## SPECIES

Canine

## BREED

Sheltie Mix

## SEX

Neutered Male

## AGE

12 Years

## WEIGHT

36 Pounds

## INTERPRETED BY

Heike Rudorf, DVM, Dr.  
med. Vet., DipECVDI  
DVR

## IMAGING PERFORMED BY

LVT

## HOSPITAL NAME

Northshore VH

## REFERRING VET

Dr. Brita Kiffney

## INVOICE

35534

## DATE

11/14/25

## PRESENTING CLINICAL SIGNS

History: 4/28/2025 had a Gastrointestinal stromal tumor (intermediate grade spindle cell sarcoma removed (Kit +) from ileocecolic junction, clean margins. Was seen here in Bellingham by an oncologist - started on Palladia and Deramax, which he did not tolerate, and this was discontinued end of June 2025. An ultrasound in June at the specialist found an ovoid mass in the caudate liver lobe, this was not sampled PAST HISTORY: Splenectomy (benign) 4/29/25 perianal gland adenoma removed 2/2023 MDR1 normal/normal mitral and tricuspid insufficiency B1 OD iris cyst surgically removed Abnormal PE/Chem/CBC/UA Results: Mild non regenerative anemia RBC 5.44 (5.84 - 8.95 M/ $\mu$ L) Hematocrit 39.3 (41.0 - 60.0 %) Hemoglobin 13.8 (14.6 - 21.7 g/dL) MCV 72 (62 - 76 fL) MCH 25.4 (22.1 - 26.7 pg) MCHC 35.1 (32.3 - 38.0 g/dL) RDW 11.5 (10.0 - 19.0 %)

Abnormal PE/Chem/CBC/UA Results: TODAY is painful in his cranial abdomen, temp is normal (101.6) and pending today's lab work . Refused to eat today.

## RADIOGRAPHIC STUDY OF THE ABDOMEN

The body condition score is 6/9 with smooth, alternating layers of fat and soft tissue opacity.

The bony structures are within normal limits.

A moderate amount of retroperitoneal fat is present. Little fat seems to surround the abdominal organs. The region between gastric fundus and kidneys is occupied by a relatively homogeneous soft tissue opacity.

The liver is located within the costal arch, and the caudo-ventral lobe is slightly rounded.

A splenic shadow is not clearly distinguishable.

Stomach and small intestine contain a physiological amount of gas. The intestinal loops are mainly located in the ventral half of the abdomen. A loss of abdominal detail close to the ventral abdominal wall results in poor differentiation of the intestinal walls in two of the lateral views. Colon and rectum contain a moderate amount of fecal matter.

Both renal shadows are visible on the lateral views due to the moderate amount of retroperitoneal fat. They have a physiological size, shape and opacity. The bladder contains a small amount of fluid and the bladder neck is located cranial to the pubic brim.

A prostatic shadow is not clearly outlined.

The sublumbar region appears physiological.

## RADIOGRAPHIC DIAGNOSIS

- Mass effect caudal to the fundus
- Localized loss of abdominal detail
- Spleen not identified (removed 4/25)

## INTERPRETATION OF THE FINDINGS & FURTHER RECOMMENDATIONS

Loss of abdominal detail is present in the region of the spleen. This could be due to localized fluid accumulation (e.g. blood, infection, carcinomatosis), may be caused by pancreatic disease with inflammation of the mesentery or could represent inflammation of the fat. The latter two would explain pain and unwillingness to eat. Abdominal ultrasound is recommended with emphasis on small intestinal loops and pancreas. Should fluid and/or intestinal masses be present, a sample should be obtained for analysis.



## PATIENT

Kobi Skeen

## SPECIES

Canine

## BREED

Sheltie Mix

## SEX

Neutered Male

## AGE

12 Years

## WEIGHT

36 Pounds

## INTERPRETED BY

Heike Rudorf, DVM, Dr.  
med. Vet., DipECVDI  
DVR

## IMAGING PERFORMED BY

LVT

## HOSPITAL NAME

Northshore VH

## REFERRING VET

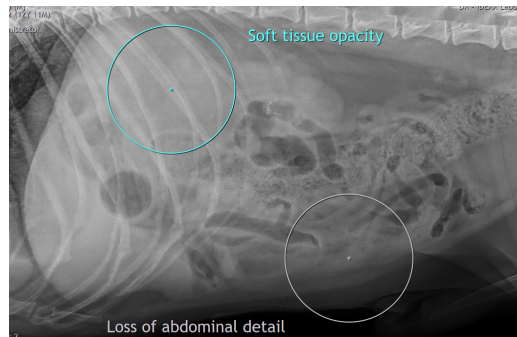
Dr. Brita Kiffney

## INVOICE

35534

## DATE

11/14/25



**The information and recommendations provided are based on the images presented by the referring veterinarian/sonographer. No evaluation can be communicated regarding pathology that was not visible in the image/video clips provided.**

Thank you for this referral. If the clinical or image interpretation does not parallel your findings or if I can be of any further assistance, please contact me.

**Heike Rudorf**, DVM, Dr. med. vet., DipECVDI, DVR  
[info@sonopath.com](mailto:info@sonopath.com)