



## PATIENT

Bear Rehfeldt

## SPECIES

Canine

## BREED

Labrador Retriever

## SEX

Neutered Male

## AGE

5 Years 9 Months

## WEIGHT

70.7 Pounds

## INTERPRETED BY

Heike Rudorf, DVM, Dr.  
med. Vet., DipECVDP  
DVR

## IMAGING PERFORMED BY

Northshore Vet Techs

## HOSPITAL NAME

Northshore VH

## REFERRING VET

Dr. Ryans Knoles

## INVOICE

35524

## DATE

11/14/25

## PRESENTING CLINICAL SIGNS

History: Presents for dermatological condition. Incidentally noted marked thickening to the left medial tarsus. Firm swelling, no overt pain on palpation. Patient sits with tarsus limited to about 90 degrees of flexion on the affected side. O does not recall a specific incidence of trauma though he does report a time that Bear presented to ER service after being clipped by a car- records were not able to be obtained. O also reports that Bear will limp after longer hikes.

Abnormal PE/Chem/CBC/UA Results: No labs taken today. No overt pain. No instability appreciated Firm mass medial aspect of the left tarsus Sits with tarsus in ~ 90 degrees of flexion.

## RADIOGRAPHIC STUDY OF THE LEFT TARSUS

### Left Tarsus

The Achilles tendon shows a caudal localized caudal swelling level with the distal tibia. Soft tissue swelling surrounds the tibio-tarsal joint but is most prominent on the medial aspect. A moderate amount of new bone (NB) is present along the medial malleolus/caudo-distal tibia; a small amount of new bone presents along the cranio-distal and lateral aspects of the calcaneal bone as well as the the cranio-distal tibia. The joint spaces are asymmetrical in width with the medial aspect reduced. Both ridges of the talus appear to be physiologically developed.

## RADIOGRAPHIC DIAGNOSIS

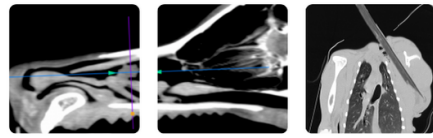
- Soft tissue swelling
- Arthrosis
- Joint space irregularity

### Incidental finding

- Focal swelling Achilles' tendon

## INTERPRETATION OF THE FINDINGS & FURTHER RECOMMENDATIONS

Changes compatible with OCD are not obvious on the DP view instead, the medial joint space is narrow suggesting cartilage damage of a different origin. Considering the history of trauma, ligaments and cartilage could have been damaged in the accident, leading to instability and new bone formation. Lameness after prolonged exercise suggests lack of cartilage and joint effusion. For the assessment of cartilage thickness and degree of damage CT arthrography or MRI would be necessary. Ultrasound can be performed to try and differentiate between effusion and fibrosis and to assess the plantar aspect of the ridges in full flexion of the joint. Comparative imaging of the Achilles tendons is recommended in case fiber disruption due to the altered weight bearing is present. The exercise regime should be adapted so that lameness can be avoided.



## PATIENT

Bear Rehfeldt

## SPECIES

Canine

## BREED

Labrador Retriever

## SEX

Neutered Male

## AGE

5 Years 9 Months

## WEIGHT

70.7 Pounds

## INTERPRETED BY

Heike Rudorf, DVM, Dr.  
med. Vet., DipECVDI  
DVR

## IMAGING PERFORMED BY

Northshore Vet Techs

## HOSPITAL NAME

Northshore VH

## REFERRING VET

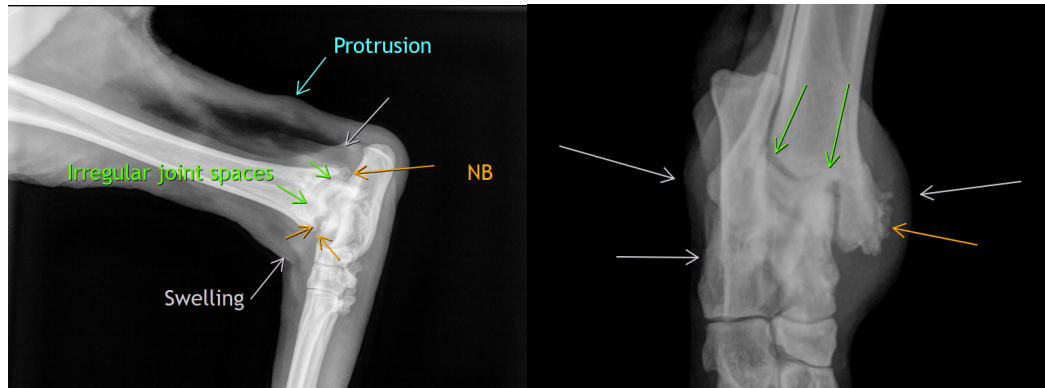
Dr. Ryans Knoles

## INVOICE

35524

## DATE

11/14/25



**The information and recommendations provided are based on the images presented by the referring veterinarian/sonographer. No evaluation can be communicated regarding pathology that was not visible in the image/video clips provided.**

Thank you for this referral. If the clinical or image interpretation does not parallel your findings or if I can be of any further assistance, please contact me.

**Heike Rudorf**, DVM, Dr. med. vet., DipECVDI, DVR  
[info@sonopath.com](mailto:info@sonopath.com)