



PATIENT

Rikash (Rikki) Parsa

PRESENTING CLINICAL SIGNS

Persistent nasal congestion and wheezing w possible nasal discharge at times and difficulty breathing through nose. Initial presentation Oct 19, 2021. No improvement with when treated for suspected upper respiratory infection with Orbax. Presented again Oct 29, 2021 and treated for possible allergic rhinitis with prednisolone but no improvement. Indoor only.

SPECIES

Feline

Abnormal PE/Chem/CBC/UA Results: Congested snuffly nasal sounds, markedly decreased to absent air movement right nostril, Gr2-3 cardiac murmur loudest right side but radiates to left side, normal temp, respiratory rate and heart rate. Some referred upper respiratory sounds but otherwise lungs clear. No additional labs at this time.

BREED

DSH

RADIOGRAPHIC STUDY OF THE THORAX

R+L lateral, 2x VD

SEX

MN

RADIOGRAPHIC FINDINGS

The body condition score is 7/9 with smooth alternating layers of fat and soft tissue opacity.

The bony structures appear physiological.

AGE

2 Years, 7 Months

The lungs are in contact with the thoracic boundaries and the tips are pointed. The lobar vessels are visible.

INTERPRETED BY

Heike Rudolf, DVM,
Dr. med. Vet.,
DipECVDDI DVR

The cranial mediastinum is of physiological size and opacity. The trachea diverges from the thoracic vertebrae and the carina is located at T5.

The cardiac silhouette occupies 75% of the chest height and 2 intercostal spaces. Both atria appear prominent which results in a slight Valentine shape of the heart.

HOSPITAL NAME

Family Pet Veterinary
Center

RADIOGRAPHIC DIAGNOSIS

- Possible bi-atrial enlargement, mild

REFERRING VET

Ryan Southard

INTERPRETATION OF THE FINDINGS & FURTHER RECOMMENDATIONS

The atria often appear prominent on a VD view even if they are normal. To rule out an early HCM, echocardiography is recommended.

A CT examination is necessary to further assess the nasal passages and rule out middle ear disease with polyp formation.

INVOICE

48305

DATE

11-12-21



PATIENT

Rikash (Rikki) Parsa

SPECIES

Feline

BREED

DSH

SEX

MN

AGE

2 Years, 7 Months

INTERPRETED BY

Heike Rudorf, DVM,
Dr. med. Vet.,
DipECVDI DVR

HOSPITAL NAME

Family Pet Veterinary
Center

REFERRING VET

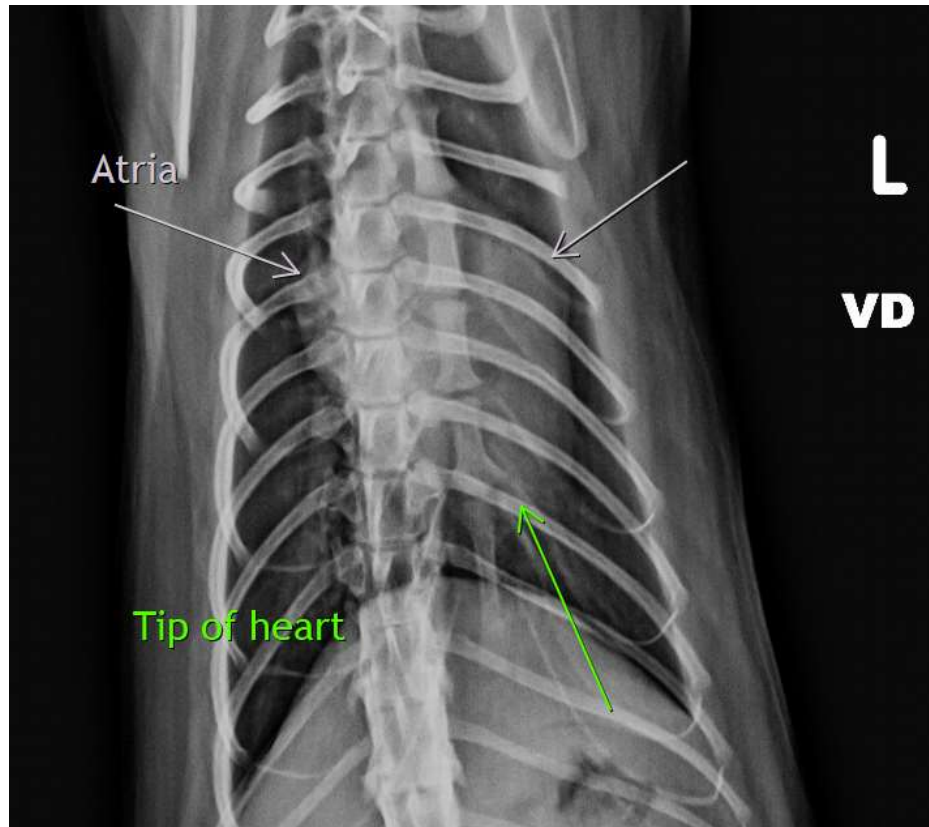
Ryan Southard

INVOICE

48305

DATE

11-12-21



The information and recommendations provided are based on the images presented by the referring veterinarian. No evaluation can be communicated regarding pathology that was not visible in the image/video clips provided.

Thank you for this referral. If the clinical or image interpretation does not parallel your findings or if I can be of any further assistance please contact me.

Heike Rudorf, DVM, Dr. med. vet., DipECVDI, DVR
Dr.H.Rudorf@gmail.com