



PATIENT PRESENTING CLINICAL SIGNS

Milo Legge acute vomiting for the last 2 days with bloody diarrhea
 Abnormal PE/Chem/CBC/UA Results: moderate abdominal discomfort BW: unremarkable

SPECIES RADIOGRAPHIC STUDY OF THE ABDOMEN

Canine RLR, LLR, DV

RADIOGRAPHIC FINDINGS

The body condition score is 6/9 with smooth alternating layers of fat and soft tissue opacity.

Siberian Husky The bony structures are within normal limits.

SEX The abdominal detail is good; diaphragm and abdominal wall are intact.

Male The liver is located within the costal arch and the caudo-ventral lobe is pointed.

The spleen appears physiological.

AGE On the VD view an almost circular soft tissue opacity of approx. 4cm diameter is located between the head of the spleen and the cranial fundic wall, displacing the fundic gas shadows. This is not apparent on the lateral views. Intestinal gas is present in different intestinal loops on all images. A physiological amount of gas in the cecum persist.

23 Months

INTERPRETED BY

Heike Rudolf, DVM, Dr. med. Vet., DipECVDI DVR Both renal shadows have a physiological size, shape and opacity; the surfaces are smooth. The bladder is located just within the abdominal cavity and contains a small amount of homogeneous fluid opacity.

HOSPITAL NAME The sublumbar region appears physiological.

St. Catherine's Animal Hospital

RADIOGRAPHIC DIAGNOSIS

- Possible space occupying lesion in region of fundus

REFERRING VET

Dr. Masoud

INTERPRETATION OF THE FINDINGS & FURTHER RECOMMENDATIONS

The change in the fundus could represent an artefact, an intraluminal gastric mass or external mass compressing the lumen. Without radiographic signs on the lateral views its significance is questionable but further examinations, either with ultrasound or a Barium study, is recommended. In association with the bloody diarrhea, a viral (e.g. parvo-, coronavirus) infection is on top of my list of differential diagnoses. An esophageal foreign body should be ruled out by obtaining a lateral thoracic view.

INVOICE

48299

DATE

11-12-21



PATIENT

Milo Legge

SPECIES

Canine

BREED

Siberian Husky

SEX

Male

AGE

23 Months

INTERPRETED BY

Heike Rudorf, DVM,
Dr. med. Vet.,
DipECVDDI DVR

HOSPITAL NAME

St. Catherine's Animal
Hospital

REFERRING VET

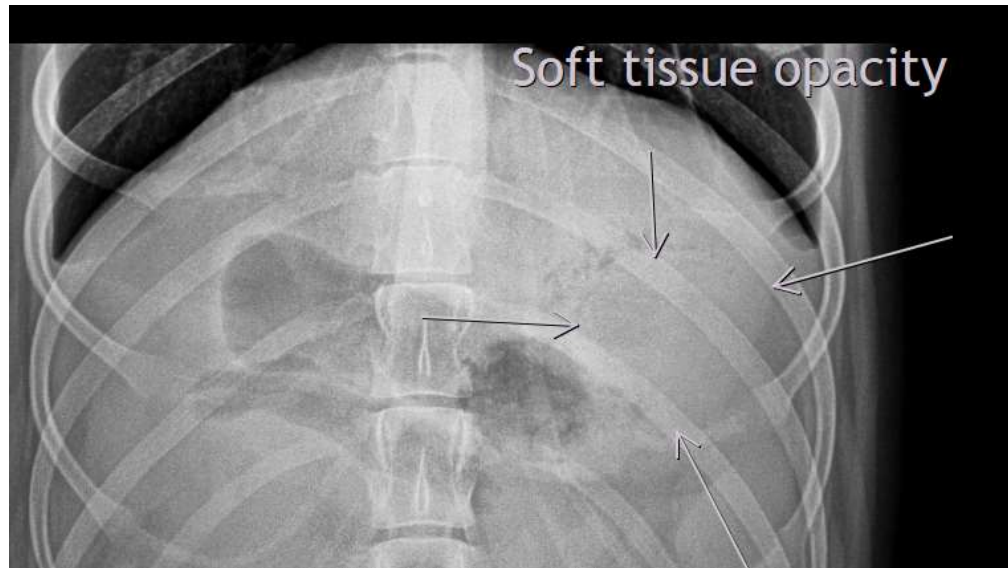
Dr. Masoud

INVOICE

48299

DATE

11-12-21



The information and recommendations provided are based on the images presented by the referring veterinarian. No evaluation can be communicated regarding pathology that was not visible in the image/video clips provided.

Thank you for this referral. If the clinical or image interpretation does not parallel your findings or if I can be of any further assistance please contact me.

Heike Rudorf, DVM, Dr. med. vet., DipECVDDI, DVR
Dr.H.Rudorf@gmail.com