



<b>PATIENT</b>	<b>PRESENTING CLINICAL SIGNS</b>
Maggie Garrett	patient is yelping in pain, unable to walk without helping, PE after admin hydro no pain noted on ortho exam
<b>SPECIES</b>	<b>RADIOGRAPHIC STUDY OF THE C-SPINE AND SHOULDERS</b>
Canine	2x lateral cervico-thoracic junction, 2 orthogonal views thoraco-lumbar junction, 1x L-spine, 1x DV thorax, 2x R lateral elbow including shoulder, 1x cranio-caudal both elbows including shoulders, 1x cranio-caudal shoulders.
<b>BREED</b>	<b>RADIOGRAPHIC FINDINGS</b>
Labrador Retriever	<u>C-spine (C3-C7)</u>
<b>SEX</b>	No signs of aggressive osteolysis have been identified.
FS	Number and shape of the vertebrae are physiological. The skeletal structures are well mineralized and have smooth surfaces.
<b>AGE</b>	The facet joints appear to be congruent.
9 Years	The disc spaces cannot be assessed.
<b>INTERPRETED BY</b>	<u>R shoulder joint</u>
Heike Rudorf, DVM, Dr. med. Vet., DipECVDDI DVR	New bone formation is present along the bicipital groove.
<b>HOSPITAL NAME</b>	<b>RADIOGRAPHIC DIAGNOSIS</b>
Boca Park Animal Hospital	<ul style="list-style-type: none"> <li>Bicipital tenosynovitis</li> </ul>
<b>REFERRING VET</b>	<b>INTERPRETATION OF THE FINDINGS &amp; FURTHER RECOMMENDATIONS</b>
Spaulding	New bone along the bicipital groove will narrow the space for the bicipital tendon and fiber disruption and effusion can occur. Ultrasound is recommended to identify this.
<b>INVOICE</b>	Accurate positioning of the spine is difficult even under G.A. and cord compression or can only be identified with myelography or cross-sectional imaging. Depending on the severity of the clinical signs, CT or MRI will be necessary in case an extruded disc needs to be removed or brachial plexus disease (e.g. inflammation, tumour) is present.
48304	<b>TECHNICAL COMMENTS</b>
<b>DATE</b>	No side markers on cranio-caudal elbows/shoulders
11-12-21	



**PATIENT**

Maggie Garrett

**SPECIES**

Canine

**BREED**

Labrador Retriever

**SEX**

FS

**AGE**

9 Years

**INTERPRETED BY**

Heike Rudorf, DVM,  
Dr. med. Vet.,  
DipECVDDI DVR

**HOSPITAL NAME**

Boca Park Animal  
Hospital

**REFERRING VET**

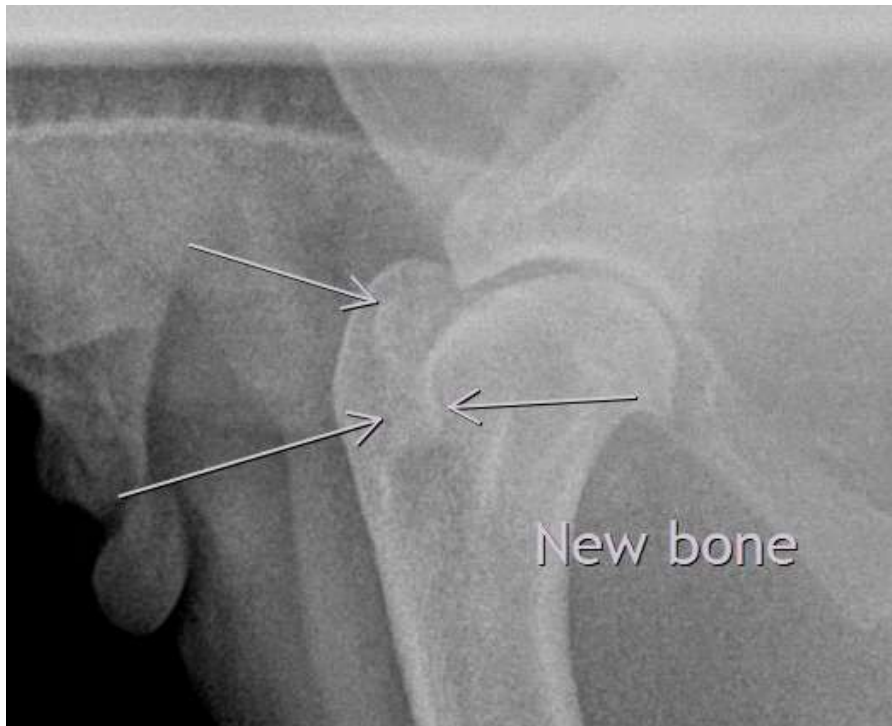
Spaulding

**INVOICE**

48304

**DATE**

11-12-21



The information and recommendations provided are based on the images presented by the referring veterinarian. No evaluation can be communicated regarding pathology that was not visible in the image/video clips provided.

Thank you for this referral. If the clinical or image interpretation does not parallel your findings or if I can be of any further assistance please contact me.

**Heike Rudorf**, DVM, Dr. med. vet., DipECVDDI, DVR  
Dr.H.Rudorf@gmail.com