



PATIENT PRESENTING CLINICAL SIGNS

Dunkin Zeppetelli History: P has been vomiting for the past month Food intolerance vs IBD vs others R/O F.B
Abnormal PE/Chem/CBC/UA Results:

SPECIES RADIOGRAPHIC STUDY OF THORAX AND ABDOMEN

Canine The body condition score is 6/9 with smooth alternating layers of fat and soft tissue opacity.

The bony structures appear physiological.

BREED

Thorax

Labrador Retriever

The lungs are in contact with the thoracic boundaries and the tips are pointed. The lobar vessels are clearly visible to the tertiary branches. The main vessels are small.

SEX

Male

The cranial mediastinum is of physiological size and opacity. The trachea diverges from the thoracic vertebrae and the carina is located at T5. A small amount of air is present in the esophagus.

AGE

1 Years

The cardiac silhouette occupies 65% of the chest height and 2 intercostal spaces. No chamber or outflow tract enlargement is evident.

Abdomen

INTERPRETED BY

The abdominal detail is good; diaphragm and abdominal wall are intact.

Heike Rudolf, DVM,
Dr. med. Vet.,
DipECVDI DVR

On the abdominal VD view multiple gas lucencies are located just caudal to the right crus of the diaphragm. I cannot see them on the lateral views.

The spleen appears physiological.

HOSPITAL NAME

Animal Paradise H

On all views the region of the pylorus is filled with soft tissue opaque material and some gas bubbles. The small intestinal loops have a physiological distribution and size. Colon and rectum contain a small amount of unformed fecal matter.

REFERRING VET

Dr. Elshafie

The left renal shadow appears of physiological size, shape and opacity; the right is obscured by intestinal loops. The bladder is located in the abdominal cavity and contains a small amount of homogeneous fluid opacity.

The sublumbar region appears physiological.

INVOICE

14270

RADIOGRAPHIC DIAGNOSIS

- Gas lucencies right cranial abdomen
- Hypoperfusion

DATE

11/11/21



PATIENT

- Microcardia

Dunkin Zeppetelli

INTERPRETATION OF THE FINDINGS & FURTHER RECOMMENDATIONS

SPECIES

Canine

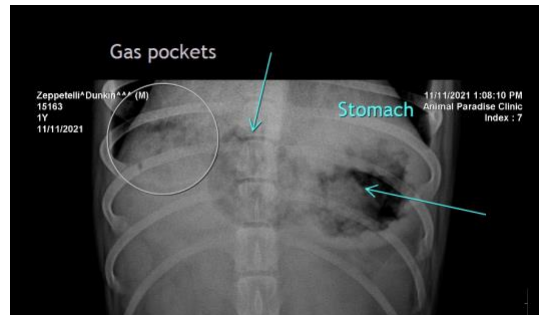
The gas lucencies may represent an abscess with gas forming organisms or could be associated with the upper GIT. However, the distribution is unusual and abdominal ultrasound is recommended to localize this gas. I can see no ileus or radiopaque foreign body. The contents of the pylorus could represent a cloth foreign body or a mixture of fluid and air. Since the history is rather long, I suggest gastroscopy to rule out a foreign object and/or to obtain biopsies. Small vessels and microcardia is probably the result of dehydration due to the chronic vomiting.

BREED

Labrador Retriever

SEX

Male



AGE

1 Years

The information and recommendations provided are based on the images presented by the referring veterinarian. No evaluation can be communicated regarding pathology that was not visible in the image/video clips provided.

INTERPRETED BY

Heike Rudolf, DVM,
Dr. med. Vet.,
DipECVDI DVR

Thank you for this referral. If the clinical or image interpretation does not parallel your findings or if I can be of any further assistance please contact me.

Heike Rudolf, DVM, Dr. med. vet., DipECVDI, DVR
dr.h.rudorf@gmail.com

HOSPITAL NAME

Animal Paradise H

REFERRING VET

Dr. Elshafie

INVOICE

14270

DATE

11/11/21