



**PATIENT PRESENTING CLINICAL SIGNS**

Stevie Nicholls History: Sudden onset of watery diarrhea  
 Abnormal PE/Chem/CBC/UA Results: mild hyperglycemia

**SPECIES RADIOGRAPHIC STUDY OF THE ABDOMEN**

Canine The body condition score is 5/9 with with a tucked up ventral abdominal wall.

**BREED** The bones are well mineralized with good trabecular structure and smooth surfaces. The disc spaces appear homogeneous in width.  
 Chinese Crested

The abdominal detail is in line with the BCS; diaphragm and abdominal wall are intact.

**SEX** The liver is located within the costal arch and the caudo-ventral lobe is pointed.

Male The spleen appears physiological.

**AGE** The stomach contains a moderate amount of air and is located within the costal arch; the small intestinal loops appear of homogeneous and physiological size. The mainly gas filled descending colon appears stretched and is extends from ribs 11 to the pelvic brim; it is mostly filled with gas and fluid.  
 20 Months

**INTERPRETED BY** The left renal shadow has a physiological size, shape and opacity; the surfaces are smooth. The right is obscured by intestinal loops. The bladder is just visible cranial to the pubic brim.

Heike Rudolf, DVM, Dr. med. Vet., DipECVDI DVR The region of the sublumbar lymph nodes appears physiological.

**RADIOGRAPHIC DIAGNOSIS**

**HOSPITAL NAME** • I can see no underlying cause for the diarrhea

St. Catharine's AH

**INTERPRETATION OF THE FINDINGS & FURTHER RECOMMENDATIONS**

**REFERRING VET** The homogeneous intestinal size suggests that neither foreign body nor intussusception are present. However, in the course of diarrhea, the intestinal motility will increase and an intussusception (sometimes sliding) may occur. In a dog such as this one, ultrasound is the best way to detect these GIT changes. I feel that viral disease may be the most likely cause for the diarrhea; food allergies are less likely. Supportive treatment is indicated to replace fluid and electrolytes.  
 Dr. Masoud

**INVOICE**

13649

**DATE**

10/8/21



**PATIENT**

Stevie Nicholls

**SPECIES**

Canine

**BREED**

Chinese Crested

**SEX**

Male

**AGE**

20 Months

**INTERPRETED BY**

Heike Rudolf, DVM,  
Dr. med. Vet.,  
DipECVDI DVR

**HOSPITAL NAME**

St. Catharine's AH

**REFERRING VET**

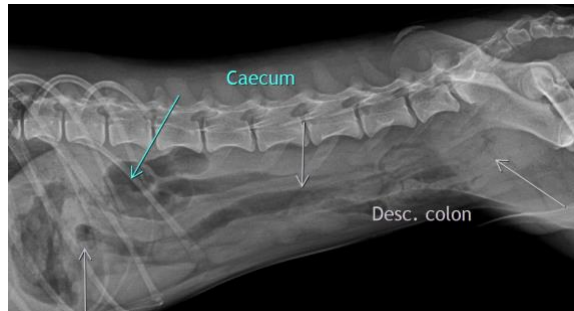
Dr. Masoud

**INVOICE**

13649

**DATE**

10/8/21



**The information and recommendations provided are based on the images presented by the referring veterinarian. No evaluation can be communicated regarding pathology that was not visible in the image/video clips provided.**

Thank you for this referral. If the clinical or image interpretation does not parallel your findings or if I can be of any further assistance please contact me.

**Heike Rudolf**, DVM, Dr. med. vet., DipECVDI, DVR  
dr.h.rudorf@gmail.com