



PATIENT PRESENTING CLINICAL SIGNS

Reno Grbic History: Fell in yard 2 days ago, now limping on left hind.
 Abnormal PE/Chem/CBC/UA Results: Limping L hind, acute onset after falling

SPECIES RADIOGRAPHIC STUDY OF THE PELVIS

Canine Age related skeletal immaturity is noted.

BREED Pelvis

Mixed Hound The muscle mass on the left thigh is reduced.

SEX

Neutered Male

The center of the left femoral head is located well lateral to the dorsal acetabular edge. The joint space is large and appears variable on the lateral view. The cranial acetabular edge straight and indistinct with new bone which has resulted in bilabiation. A moderate amount of new bone formation is located along the femoral neck. On the right side the centre of the femoral head is only just lateral to the dorsal acetabula edge and the amount of new bone formation is also less marked than on the left.

AGE

11 Months

Left Stifle

The stifle joint has smooth subchondral bone surfaces and the centre of the femoral condyles is in line with the intercondylar eminence. The cranial fat pad has a physiological size and the caudal fascial plains are in a physiological position. New bone formation is not evident and the patella is located in its groove.

INTERPRETED BY

Heike Rudolf, DVM,
 Dr. med. Vet.,
 DipECVDI DVR

RADIOGRAPHIC DIAGNOSIS

HOSPITAL NAME

New Bridge VP

- Bilateral HD, severe on the left
- Bilateral hip arthrosis, severe on left
- Muscle atrophy, left

INTERPRETATION OF THE FINDINGS & FURTHER RECOMMENDATIONS

REFERRING VET

Dr. Abina Glennon

The sever changes in the left hip joint are very likely the cause for pain and lameness. A joint effusion may now be present or the muscle fibers may be damaged as a result of the fall. Conservative treatment is recommended and hydro- or physiotherapy should be employed later to increase the muscle mass as this will, in turn, increase the stability of the joint. Total hip replacement needs to be discussed.

INVOICE

13637

DATE

10/8/21



PATIENT

Reno Grbic

SPECIES

Canine

BREED

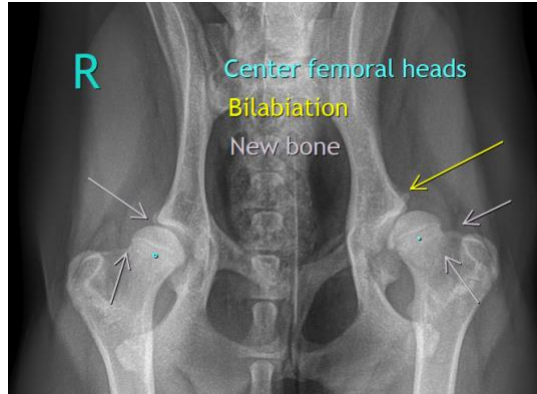
Mixed Hound

SEX

Neutered Male

AGE

11 Months



The information and recommendations provided are based on the images presented by the referring veterinarian. No evaluation can be communicated regarding pathology that was not visible in the image/video clips provided.

Thank you for this referral. If the clinical or image interpretation does not parallel your findings or if I can be of any further assistance please contact me.

Heike Rudolf, DVM, Dr. med. vet., DipECVDI, DVR
dr.h.rudorf@gmail.com

INTERPRETED BY

Heike Rudolf, DVM,
Dr. med. Vet.,
DipECVDI DVR

HOSPITAL NAME

New Bridge VP

REFERRING VET

Dr. Abina Glennon

INVOICE

13637

DATE

10/8/21