



PATIENT PRESENTING CLINICAL SIGNS

Sophia Rose Magana History: Worsening cough, history of nasal tumor, collapsing trachea. ON temeril P 1/2 tab SID, Hycodan now 2x daily past 3 days. Hacking cough, occ bloody nasal discharge.

SPECIES Abnormal PE/Chem/CBC/UA Results: No heart murmur ausc. Crackled L>R side, tracheal cough, clear nasal discharge.

Canine

RADIOGRAPHIC STUDY OF THE THORAX

BREED The body condition score is 8/9 with a reticular pattern of the soft tissues on the DV views.

Toy Poodle The bony structures appear physiological.

SEX The lungs are in contact with the thoracic boundaries and the tips are pointed. The lobar vessels are visible. The main stem bronchi appear large and the left narrows down abruptly at the first branching region.

Spayed Female

AGE The cranial mediastinum is of physiological size and opacity. The trachea runs parallel to the thoracic vertebrae and dips at the carina. The lumen varies in size. The main stem bronchi are not evident in left lateral recumbency and the terminal tracheal lumen is severely reduced by a dorsal soft tissue opacity.

12 Years

The cardiac silhouette occupies 85% of the chest height and 3 intercostal spaces (VHS 10). On the DV view the impression is that of a reversed D-shape without obvious pulmonary artery enlargement.

INTERPRETED BY

Heike Rudolf, DVM,
Dr. med. Vet.,
DipECVDI DVR

RADIOGRAPHIC DIAGNOSIS

- Tracheal collapse
- Possible bronchial collapse

HOSPITAL NAME

Bergan County VC

INTERPRETATION OF THE FINDINGS & FURTHER RECOMMENDATIONS

Tracheal collapse alone can be due to a weakened dorsal tracheal ligament. Tracheal in combination with bronchial collapse is usually caused by chondromalacia and is thus due to an altered cartilage development, which may go unnoticed until physical circumstances (such as stress, running, excitement) or disease (e.g. pneumonia, bronchitis, left cardiac enlargement) reduces the ease of airflow. Echocardiography to assess mitral valve and left atrial size and bronchoscopy to obtain a BAL is recommended. Should an underlying disease be present treatment may improve the clinical signs. However, if a nasal tumour is present, this alone will be enough to worsen the collapse.

REFERRING VET

Dr. Lewis

INVOICE

13608

DATE

10/7/21



PATIENT

Sophia Rose Magana

SPECIES

Canine

BREED

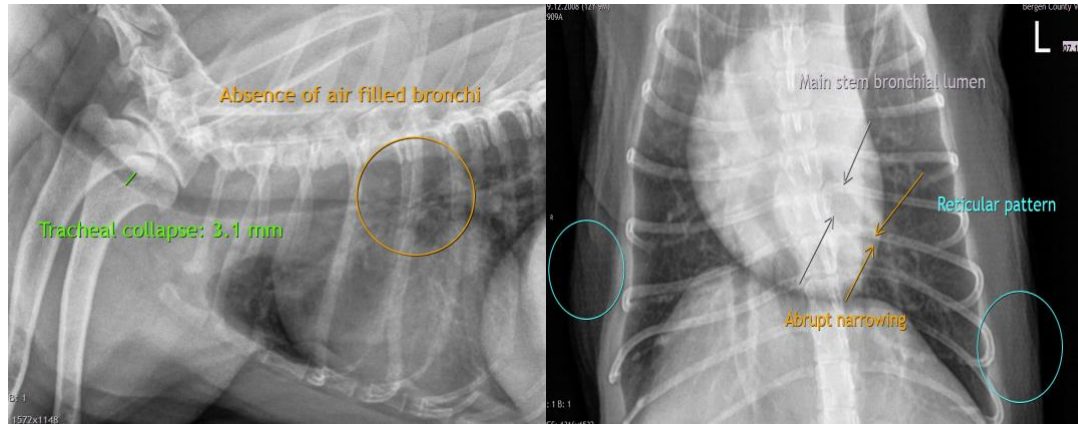
Toy Poodle

SEX

Spayed Female

AGE

12 Years



The information and recommendations provided are based on the images presented by the referring veterinarian. No evaluation can be communicated regarding pathology that was not visible in the image/video clips provided.

Thank you for this referral. If the clinical or image interpretation does not parallel your findings or if I can be of any further assistance please contact me.

Heike Rudolf, DVM, Dr. med. vet., DipECVDI, DVR
dr.h.rudorf@gmail.com

INTERPRETED BY

Heike Rudolf, DVM,
Dr. med. Vet.,
DipECVDI DVR

HOSPITAL NAME

Bergan County VC

REFERRING VET

Dr. Lewis

INVOICE

13608

DATE

10/7/21