



PATIENT PRESENTING CLINICAL SIGNS

PATIENT Oliver Lacroix
SPECIES History: Rads done in early sept 2/21, diagnosed bronchiole interstitial pattern possible asthma. Blood work, evidence of mild pancreatitis. Eye issues, inflamed right eye, conjunctiva, third eyelid. Inflammation went away with meds. Now dilated pupil, mass in right side of mouth seen under anesthetic. 47320 invoice number.

Abnormal PE/Chem/CBC/UA Results:

Feline

RADIOGRAPHIC STUDY OF THE HEAD

BREED On the rostro-caudal view the right frontal sinus shows a mildly increased soft tissue opacity with lucent stipples. The right nasal chamber appears of homogeneous soft tissue opacity with a loss of turbinate structures.
DSH

SEX The highlighted bulla on the oblique views appears physiological.

RADIOGRAPHIC DIAGNOSIS

Neutered Male

Right

- AGE**
- Soft tissue opacity nasal cavity and destruction of turbinates
 - Possibly frontal sinus involvement

14 Years

INTERPRETATION OF THE FINDINGS & FURTHER RECOMMENDATIONS

INTERPRETED BY

Heike Rudorf, DVM, Dr. med. Vet., DipECVDI DVR
 The changes are highly suggestive of a nasal tumor that has invaded the orbit. CT or rhinoscopy with biopsy are necessary to confirm this suspicion. The increased opacity in the frontal sinus could be an artefact, represent fluid or mass invasion.

HOSPITAL NAME

Sunridge VC

REFERRING VET

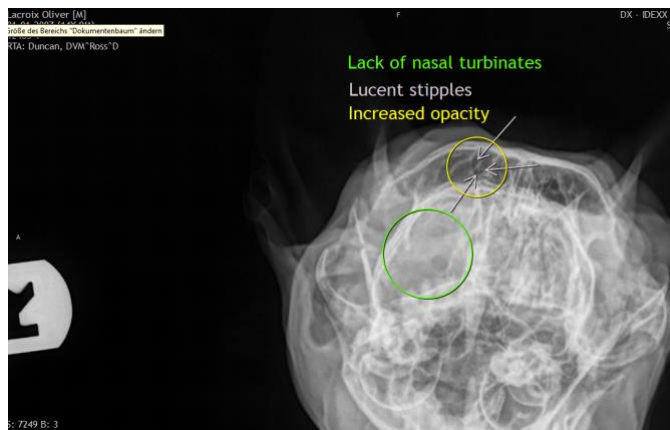
Dr. Barry Magill

INVOICE

13606

DATE

10/7/21



The information and recommendations provided are based on the images presented by the



PATIENT referring veterinarian. No evaluation can be communicated regarding pathology that was not visible in the image/video clips provided.

Oliver Lacroix

Thank you for this referral. If the clinical or image interpretation does not parallel your findings or if I can be of any further assistance please contact me.

SPECIES

Feline

Heike Rudorf, DVM, Dr. med. vet., DipECVDI, DVR
dr.h.rudorf@gmail.com

BREED

DSH

SEX

Neutered Male

AGE

14 Years

INTERPRETED BY

Heike Rudorf, DVM,
Dr. med. Vet.,
DipECVDI DVR

HOSPITAL NAME

Sunridge VC

REFERRING VET

Dr. Barry Magill

INVOICE

13606

DATE

10/7/21