

**PATIENT**

Moose Duncan

PRESENTING CLINICAL SIGNS

History: Send previous radiographs (sept 3, 2021) these three radiographs are from 2 days after starting steroid treatment for Asthma. Please comment and compare to previous submission Duncan- moose-47342ch HR

SPECIES

Canine

Abnormal PE/Chem/CBC/UA Results:

RADIOGRAPHIC STUDY OF THE THORAX**BREED**

Pitbull

The degree of pulmonary expansion is fair at best. The lung infiltrate is now patchy, fluffy, cloudy with air bronchograms whereas previously a broncho-interstitial pattern prevailed. The other structures are as before.

RADIOGRAPHIC DIAGNOSIS**SEX**

Neutered Male

- Alveolar infiltrate, generalized

INTERPRETATION OF THE FINDINGS & FURTHER RECOMMENDATIONS**AGE**

7 Years

The previously submitted radiographs show a broncho-interstitial pattern. The recommendation at the time was echocardiography to rule out DCM as well as BAL. The fact that an alveolar pattern has developed two days after steroid treatment commenced, is compatible with infection. However, edema and hemorrhage are radiological differential diagnoses, granulomatous infiltrate is unlikely. A sample has to be obtained and sent to bacteriology and sensitivity testing. After obtaining the sample, treatment with a broad-spectrum antibiotic should be initiated and changed according to the result of the sensitivity test. Prior to this, pulmonary edema due to cardiogenic or non-cardiogenic causes has to be ruled out.

INTERPRETED BY

Heike Rudorf, DVM,
Dr. med. Vet.,
DipECVDI DVR

TECHNICAL COMMENTS

Only jpg images were submitted. The transformation from DICOM to jpg reduces the image quality and only allows limited manipulation of the image. More subtle lesions can thus easily be missed. For the best possible imaging reports I suggest submitting DICOM images in the future.

HOSPITAL NAME

Sunridge VC

REFERRING VET

Dr. Ross Duncan

INVOICE

13601

DATE

10/7/21



PATIENT

Moose Duncan

SPECIES

Canine

BREED

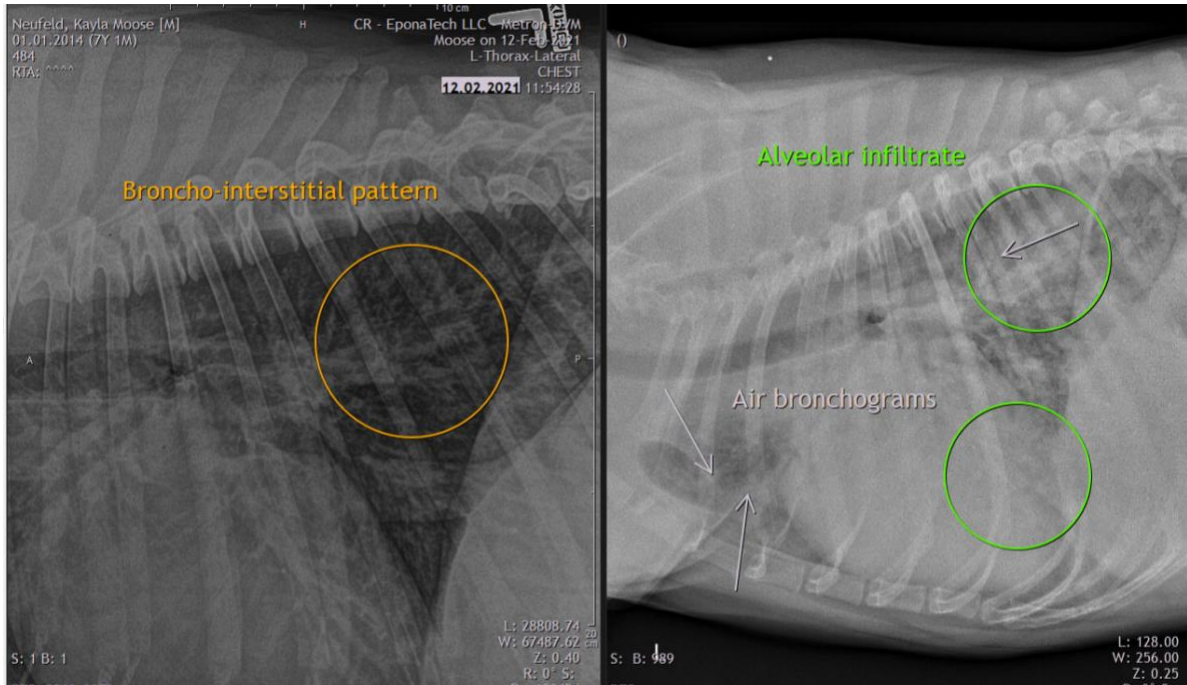
Pitbull

SEX

Neutered Male

AGE

7 Years



The information and recommendations provided are based on the images presented by the referring veterinarian. No evaluation can be communicated regarding pathology that was not visible in the image/video clips provided.

Thank you for this referral. If the clinical or image interpretation does not parallel your findings or if I can be of any further assistance please contact me.

INTERPRETED BY

Heike Rudorf, DVM,
Dr. med. Vet.,
DipECVDI DVR

Heike Rudorf, DVM, Dr. med. vet., DipECVDI, DVR
dr.h.rudorf@gmail.com

HOSPITAL NAME

Sunridge VC

REFERRING VET

Dr. Ross Duncan

INVOICE

13601

DATE

10/7/21