

**PATIENT**

Lemon Larkin

PRESENTING CLINICAL SIGNS

History: Owner reports several months of progressive lameness on front right leg. Mild crepitus in elbow. No reaction to deep digital palpation of bicipital tendon. Stoic dog.

SPECIES

Canine

Abnormal PE/Chem/CBC/UA Results:

RADIOGRAPHIC STUDY OF SHOULDERS AND ELBOWS

On the cr-cd image of the right scapula a mineral opaque line extends from the latero-distal periphery of the image to the scapula. This is not evident on the other images.

BREED

English Bulldog

The long bones, right scapula and visible ribs are well mineralized, have a normal trabecular structure and smooth surfaces. Cortical-medullary development and differentiation are physiological.

SEX

Intact Female

The shoulder joints appear congruent with even subchondral bone surfaces.

The elbow joints are congruent with smooth periosteal and subchondral bone surfaces. A mild increase in opacity is present along both semilunar notches.

AGE

1.2 Years

RADIOGRAPHIC DIAGNOSIS

- I can see no changes that would explain the clinical signs
- Radiopaque line on one view only

INTERPRETATION OF THE FINDINGS & FURTHER RECOMMENDATIONS**INTERPRETED BY**

Heike Rudolf, DVM,
Dr. med. Vet.,
DipECVDI DVR

The absence of radiographic changes does not rule out medial coronoid pathology and since crepitus is present, I suggest a CT examination of both elbow joints. Inflammation of the extensor tendons due to trauma may be present and can be detected after the administration of i.v. contrast.

The radiopaque line most likely represents an artefact due to something between table and animal.

HOSPITAL NAME

East Bend AH

TECHNICAL COMMENTS

Non DICOM images were submitted. The transformation from DICOM to (e.g.) jpg reduces the image quality and only allows limited manipulation of the image. More subtle lesions can thus easily be missed. For the best possible imaging reports I suggest submitting DICOM images in the future.

REFERRING VET

Dr. Dalton Webb

INVOICE

13603

DATE

10/7/21



PATIENT

Lemon Larkin

SPECIES

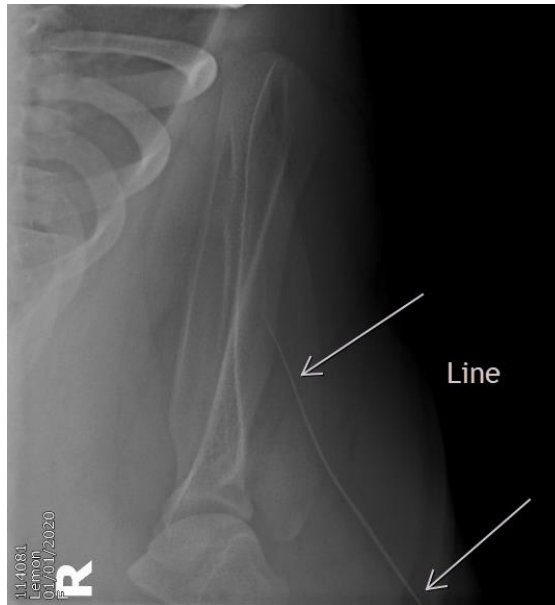
Canine

BREED

English Bulldog

SEX

Intact Female



AGE

1.2 Years

The information and recommendations provided are based on the images presented by the referring veterinarian. No evaluation can be communicated regarding pathology that was not visible in the image/video clips provided.

Thank you for this referral. If the clinical or image interpretation does not parallel your findings or if I can be of any further assistance please contact me.

Heike Rudolf, DVM, Dr. med. vet., DipECVDI, DVR
dr.h.rudorf@gmail.com

INTERPRETED BY

Heike Rudolf, DVM,
Dr. med. Vet.,
DipECVDI DVR

HOSPITAL NAME

East Bend AH

REFERRING VET

Dr. Dalton Webb

INVOICE

13603

DATE

10/7/21