

**PATIENT**

Kona Oseguera

PRESENTING CLINICAL SIGNS

P presented for a second opinion on a previously diagnosed "heavily granulated mast cell tumor". Surgery with specialists had been advised earlier in the year, but O's were unsure about surgery with specialists, oncology, or other therapy.

SPECIES

Canine

Abnormal PE/Chem/CBC/UA Results: 5cm x 10cm, firm, globoid, SQ mass w/ pendulous attachment on the cranial aspect of the left forelimb antebrachium (FNA revealed mast cell tumor).

BREED

Pit Bull

RADIOGRAPHIC STUDY OF THE THORAX

Thorax 2xLLR, RLR, VD
Abdomen: RLR, LLR, VD

RADIOGRAPHIC FINDINGS**SEX**

FS

The body condition score is 7/9 with smooth alternating layers of fat and soft tissue opacity.

The bony structures appear physiological.

AGE

6 Years

The lungs are in contact with the thoracic boundaries and the tips are pointed. The lobar vessels are clearly visible to the tertiary branches. The bronchial tree is thin walled and tapers uniformly towards the periphery; calcification of the main stem bronchi is evident.

INTERPRETED BY

Heike Rudolf, DVM,
Dr. med. Vet.,
DipECVDDI DVR

The cranial mediastinum is of physiological size and opacity. The trachea diverges from the thoracic vertebrae and the carina is located at T6. A small amount of air is present in the thoracic esophagus.

The cardiac silhouette occupies 75% of the chest height and 2.5 intercostal spaces (VHS 10.5). No chamber or outflow tract enlargement is evident.

HOSPITAL NAME

Boca Park Animal
Hospital

RADIOGRAPHIC DIAGNOSIS

- Bronchial calcification, mild

REFERRING VET

Tifanie Silver

INTERPRETATION OF THE FINDINGS & FURTHER RECOMMENDATIONS

I can see no nodular opacities in the lungs. Mast cell tumors tend to metastasize to liver and spleen thus abdominal ultrasound is recommended and samples should be obtained.

INVOICE

48097

DATE

10-30-21



PATIENT

Kona Oseguera

SPECIES

Canine

BREED

Pit Bull

SEX

FS

AGE

6 Years

INTERPRETED BY

Heike Rudolf, DVM,
Dr. med. Vet.,
DipECVDI DVR

HOSPITAL NAME

Boca Park Animal
Hospital

REFERRING VET

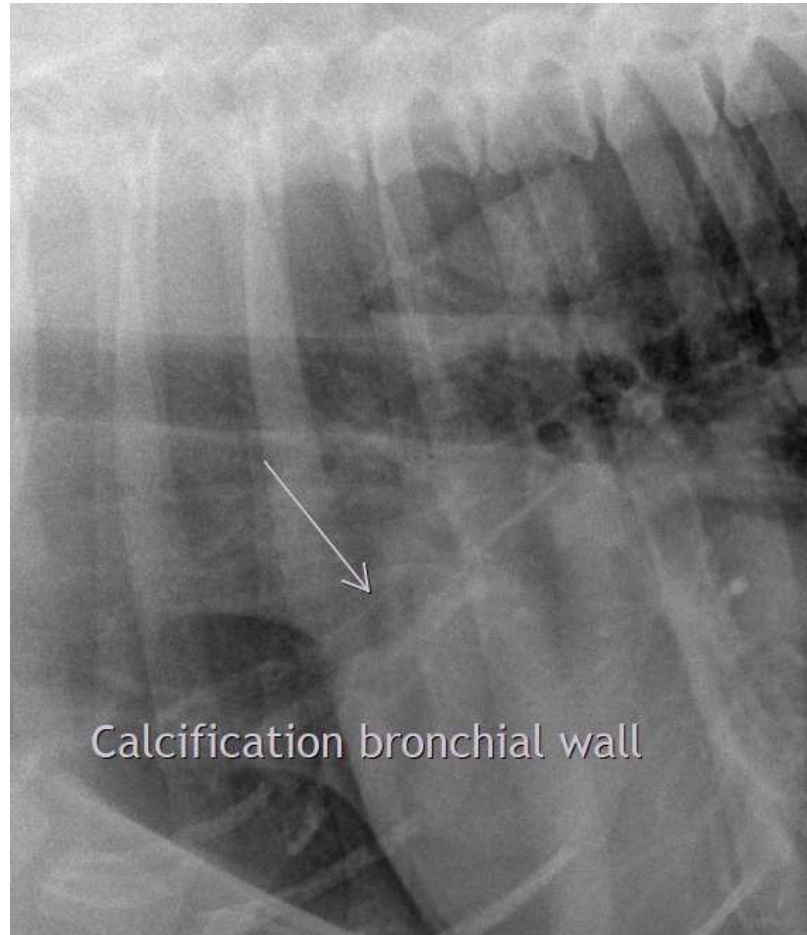
Tifanie Silver

INVOICE

48097

DATE

10-30-21



The information and recommendations provided are based on the images presented by the referring veterinarian. No evaluation can be communicated regarding pathology that was not visible in the image/video clips provided.

Thank you for this referral. If the clinical or image interpretation does not parallel your findings or if I can be of any further assistance please contact me.

Heike Rudolf, DVM, Dr. med. vet., DipECVDI, DVR
Dr.H.Rudorf@gmail.com