



PATIENT PRESENTING CLINICAL SIGNS

PATIENT Reggie Snider History: History of patellar luxation long time ago

SPECIES Abnormal PE/Chem/CBC/UA Results: bilateral patellar luxation, pain during palpation at the level of the stifle, BW was performed 4 months ago , liver enzymes mild elevated.

Canine RADIOGRAPHIC STUDY OF THE STIFLES

BREED Both stifle joints have smooth subchondral bone surfaces, and the centre of the femoral condyles is in line with the intercondylar eminence. The cranial fat pad has a physiological size, and the caudal fascial plains are in a physiological position. New bone formation is not evident and both patellae are located in their respective groove.
Yorkshire Terrier

SEX The centre of both femoral heads is located just lateral to the respective dorsal acetabular edge. The cranial joint space of both hip joints is increased, the cranial acetabular edges are mildly sclerotic, and a sclerotic rim is present level with the joint capsule.
Neutered Male

RADIOGRAPHIC DIAGNOSIS

AGE
 8 Years

- Hip subluxation, mild

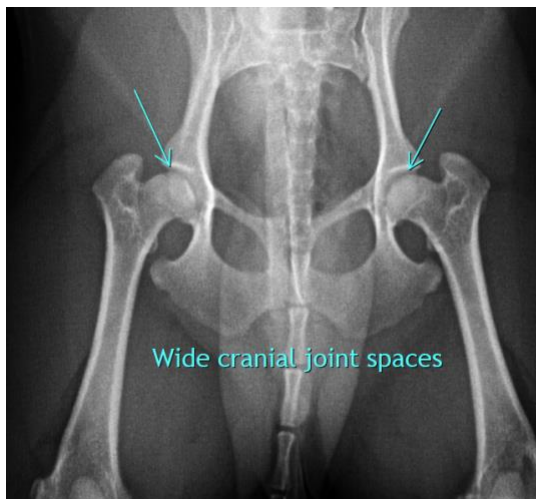
INTERPRETATION OF THE FINDINGS & FURTHER RECOMMENDATIONS

INTERPRETED BY The grade 1 and 2 patella luxation is not demonstrable on the standard views and I can see no secondary bony changes. The HD is an incidental finding but should be investigated further if lameness is present.
 Heike Rudorf, DVM,
 Dr. med. Vet.,
 DipECVDDI DVR

HOSPITAL NAME
 ST. Catharine's AH

REFERRING VET
 Dr. Masoud

INVOICE
 14081



DATE The information and recommendations provided are based on the images presented by the
 10/29/21



PATIENT referring veterinarian. No evaluation can be communicated regarding pathology that was not visible in the image/video clips provided.

Reggie Snider

Thank you for this referral. If the clinical or image interpretation does not parallel your findings or if I can be of any further assistance please contact me.

SPECIES **Heike Rudolf**, DVM, Dr. med. vet., DipECVDI, DVR
dr.h.rudorf@gmail.com

Canine

BREED

Yorkshire Terrier

SEX

Neutered Male

AGE

8 Years

INTERPRETED BY

Heike Rudolf, DVM,
Dr. med. Vet.,
DipECVDI DVR

HOSPITAL NAME

ST. Catharine's AH

REFERRING VET

Dr. Masoud

INVOICE

14081

DATE

10/29/21