



PATIENT PRESENTING CLINICAL SIGNS

PATIENT Gracie Correa
HISTORY: Reason for Visit: Coughing/Hacking History: P presents for coughing and hacking for past couple of days. P is INDOOR ONLY and all her cats are indoor only as well. P has been less active and eating less. P has no discharge coming from nose or eyes. On Sunday P was exposed to smoke after O left plastic in oven.

SPECIES Feline
ABNORMAL PE/CHEM/CBC/UA RESULTS CV/RESPIRATORY: No murmur, lungs clear, not in respiratory distress
DIAGNOSTIC TESTING NEEDED: cbc/chem - suspect band neutrophilia, neutrophils 9,030, monos upper end normal, Chest/neck rads - tracheal narrowing...r/o inflammation/swelling vs less likely collapsing trachea. Mild bronchial pattern

BREED SSH
RADIOGRAPHIC STUDY OF THE THORAX

The body condition score (BCS) is 7/9 with smooth alternating layers of fat and soft tissue opacity. The bony structures appear physiological.

SEX Spayed Female
 The lungs are in contact with the thoracic boundaries and the tips are pointed. The lobar vessels are visible, some bronchi are highlighted.

AGE 2 Years 3 Months
 The cranial mediastinum is of physiological size and crescent shaped, soft tissue structure is superimposed onto the dorsal tracheal air space between C3 and T2. The dorsal tracheal outline is still visible.

The cardiac silhouette is surrounded by fat on the DV view. It occupies 75% of the chest height and 2.5 intercostal spaces on the lateral view. No chamber or outflow tract enlargement is evident.

INTERPRETED BY Heike Rudolf, DVM, Dr. med. Vet., DipECVDI DVR
RADIOGRAPHIC DIAGNOSIS

- Broncho-interstitial pattern, mild
- Possible tracheal narrowing

HOSPITAL NAME DPC Veterinary H
INTERPRETATION OF THE FINDINGS & FURTHER RECOMMENDATIONS

Tracheal collapse is uncommon in cats, and I thus feel that the dorsal soft tissue opacity represents a superimposed esophagus. To confirm this, Barium esophagography or tracheoscopy are necessary. The pulmonary changes could be artifacts due to the BCS. However, bronchitis can be present without radiographic evidence. Trachea-bronchoscopy with broncho-alveolar lavage is recommended. During this examination pharynx and larynx can be assessed for masses (e.g. tonsils), inflammation and vocal cord abnormalities.

INVOICE 14077
TECHNICAL COMMENTS

The muscles of the fore legs are superimposed onto the cranial thorax

DATE 10/29/21

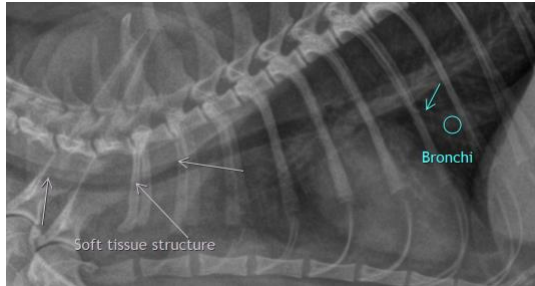


PATIENT

Gracie Correa

SPECIES

Feline



BREED

SSH

The information and recommendations provided are based on the images presented by the referring veterinarian. No evaluation can be communicated regarding pathology that was not visible in the image/video clips provided.

SEX

Spayed Female

Thank you for this referral. If the clinical or image interpretation does not parallel your findings or if I can be of any further assistance please contact me.

Heike Rudolf, DVM, Dr. med. vet., DipECVDI, DVR
dr.h.rudorf@gmail.com

AGE

2 Years 3 Months

INTERPRETED BY

Heike Rudolf, DVM,
Dr. med. Vet.,
DipECVDI DVR

HOSPITAL NAME

DPC Veterinary H

REFERRING VET

Dr. Feldt

INVOICE

14077

DATE

10/29/21