



PATIENT

Hudson Sorley

PRESENTING CLINICAL SIGNS

Dr. Sorley stated that Hudson has been coughing and is exacerbated when he eats or drinks. Dr. Sorley stated Hudson does have allergies but due to his age would like chest and esophageal xrays to rule out cancer or mega esophagus. Dr. Sorley stated the allergies do contribute to his cough but since the weather is getting colder his allergies are calming down.
 Abnormal PE/Chem/CBC/UA Results: nothing abnormal was found in the examination.

SPECIES

Canine

RADIOGRAPHIC STUDY OF THORAX AND NECK

BREED

Irish Setter

Thorax: RLR, LLR, VD
 Neck: 2 orthogonal views

RADIOGRAPHIC FINDINGS

SEX

Male

Thorax

The body condition score is 5/9 with smooth alternating layers of fat and soft tissue opacity.

AGE

11 Years

Ventral spondylosis is present on various thoracic vertebrae. New bone surrounds the intersternbral spaces. A small amount of new bone formation is evident on one caudal scapula and humeral head.

INTERPRETED BY

Heike Rudolf, DVM,
 Dr. med. Vet.,
 DipECVDI DVR

The lungs are in contact with the thoracic boundaries and the tips are pointed. The lobar vessels are clearly visible to the tertiary branches. The bronchial tree is thin walled, partially calcified and tapers uniformly towards the periphery.

HOSPITAL NAME

Elizabeth Animal
 Hospital

The cranial mediastinum is of physiological size and opacity. The trachea diverges from the thoracic vertebrae and the carina is located at T5. A straight tubular structure between diaphragm and carina on the right lateral recumbent view represents the esophagus.

The cardiac silhouette occupies 65% of the chest height and 2.5 intercostal spaces. A small bulge is present at 2 o'clock.

Neck

REFERRING VET

Kim Allyn, DVM

The C-spine is slightly rotated. The hyoid apparatus is thus not completely superimposed. One thyrohyoid bone appears to consist of 3 parts and the most caudo-dorsal part appears thicker. Mild calcification of both terminal horizontal ear canals is present.

RADIOGRAPHIC DIAGNOSIS

INVOICE

47937

- Bronchial calcification
- Bulge at 2 o'clock
- Spondylosis
- New bone sternum
- Shoulder arthrosis, mild
- Calcification horizontal ear canals, mild

DATE

10-22-21



PATIENT

Hudson Sorley

INTERPRETATION OF THE FINDINGS & FURTHER RECOMMENDATIONS

The esophagus is not enlarged, and no aspiration pneumonia is present.

SPECIES

Canine

The mild bronchial calcification is most likely age related but could be the response to chronic inflammation. The bulge at 2 o'clock represents the pulmonary artery segment and is most likely visible due to the recumbency and well inflated lungs rather than because it is enlarged. However, only echocardiography can definitely rule out enlargement due to early pulmonary hypertension.

BREED

Irish Setter

The apparent changes of one thyrohyoid bone could be the result of rotation combined with superimpositioning of soft tissue structures and air. Considering the clinical signs, visual inspection of the pharynx is recommended. Tonsillar enlargement should be ruled out.

SEX

Male

AGE

11 Years

INTERPRETED BY

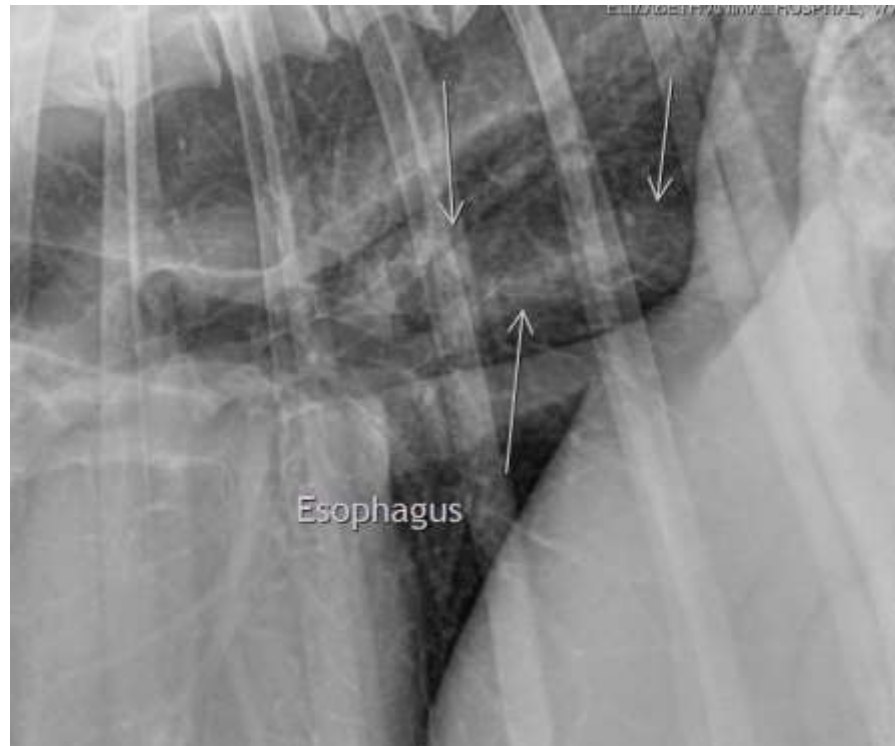
Heike Rudorf, DVM,
Dr. med. Vet.,
DipECVDDI DVR

HOSPITAL NAME

Elizabeth Animal
Hospital

REFERRING VET

Kim Allyn, DVM



INVOICE

47937

DATE

10-22-21



PATIENT

Hudson Sorley

SPECIES

Canine

BREED

Irish Setter

SEX

Male

AGE

11 Years

INTERPRETED BY

Heike Rudorf, DVM,
Dr. med. Vet.,
DipECVDI DVR

HOSPITAL NAME

Elizabeth Animal
Hospital

REFERRING VET

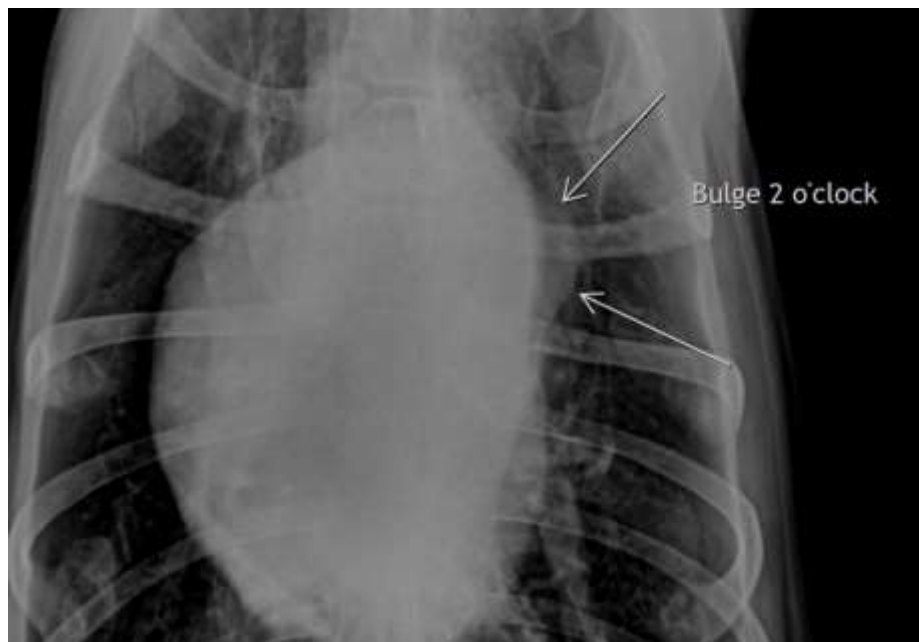
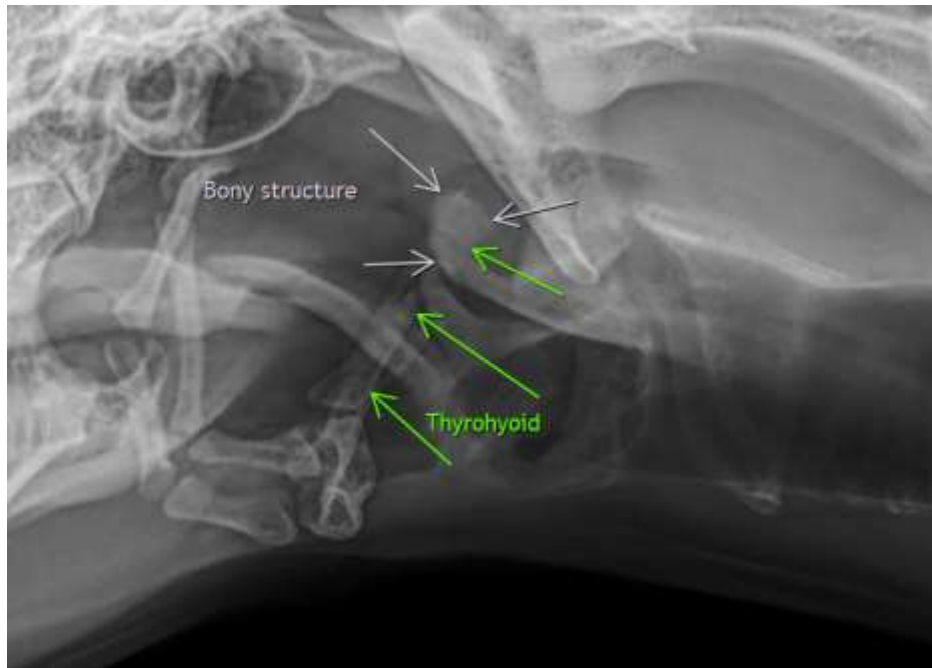Kim Allyn, DVM

INVOICE

47937

DATE

10-22-21





PATIENT

Hudson Sorley

The information and recommendations provided are based on the images presented by the referring veterinarian. No evaluation can be communicated regarding pathology that was not visible in the image/video clips provided.

SPECIES

Canine

Thank you for this referral. If the clinical or image interpretation does not parallel your findings or if I can be of any further assistance please contact me.

BREED

Irish Setter

Heike Rudorf, DVM, Dr. med. vet., DipECVDI, DVR
Dr.H.Rudorf@gmail.com

SEX

Male

AGE

11 Years

INTERPRETED BY

Heike Rudorf, DVM,
Dr. med. Vet.,
DipECVDI DVR

HOSPITAL NAME

Elizabeth Animal
Hospital

REFERRING VET

Kim Allyn, DVM

INVOICE

47937

DATE

10-22-21